

HEALING OF BURNS IN RESPONSE TO PIGSKIN HETEROGRAFTS

---

A THESIS

SUBMITTED IN PARTIAL FULFILLMENT OF THE REQUIREMENTS

FOR THE DEGREE OF MASTER OF SCIENCE

IN THE GRADUATE SCHOOL OF THE

TEXAS WOMAN'S UNIVERSITY

COLLEGE OF NURSING

BY

ELIZABETH I. HELVIG, B.S.N.

---

DALLAS, TEXAS

MAY, 1977

The Graduate School  
Texas Woman's University  
Denton, Texas

November 15 19 76

We hereby recommend that the Thesis prepared under  
our supervision by Elizabeth L. Helwig  
entitled "Healing of Burns in Response to  
Pigskin Heterografts"

be accepted as fulfilling this part of the requirements for the Degree of  
Master of Science

Committee:

Hendine M. Horzen  
Chairman

Charles K. Huxton, M.D.  
Paul J. Huxton, Ph.D.  
Barbara A. Carter Ed.D.

Accepted:

\_\_\_\_\_  
Dean of The Graduate School

## ACKNOWLEDGEMENTS

This work was supported by contract N01-NU-34014 with the National Institutes of Health, Division of Nursing, Department of Health, Education and Welfare.

I wish to express my sincere appreciation to Charles R. Baxter, M.D., F.A.C.S., Professor of Surgery, Southwestern Medical School, for his guidance and encouragement throughout this graduate program.

The suggestions of Geraldine Goosen, R.N., M.S.; Bernard Rubal, Ph.D.; Barbara Carper, R.N., Ed.D.; and Cornelia Kenner, R.N., M.S. in the preparation of this paper have been very much appreciated.

I would also like to express my gratitude to Ellen Heck, B.S., M.T. for her technical assistance in developing and carrying out this study.

I wish to thank Marge Head, L.P.T., Chief Physical Therapist and the other persons staffing the physical therapy department for their cooperation and assistance in the collection of the data.

Special thanks also to Robert Freeman, M.D., Clinical Professor of Pathology for his biopsy interpretations and to Richard Browne, Ph.D. for his suggestions with regard to statistical analysis of the data.

## TABLE OF CONTENTS

|   | Page |
|---|------|
| ACKNOWLEDGEMENTS . . . . .  | iii  |
| TABLE OF CONTENTS . . . . .   | iv   |
| LIST OF TABLES . . . . .  | vi   |
| <br>Chapter   |      |
| I. INTRODUCTION . . . . .   | 1    |
| Statement of Problem . . . . .  | 1    |
| Purposes . . . . .  | 2    |
| Background and Significance . . . . .   | 2    |
| Hypotheses . . . . .  | 7    |
| Definition of Terms . . . . .   | 7    |
| Limitations . . . . .   | 8    |
| Delimitations . . . . .   | 9    |
| Assumptions . . . . .   | 9    |
| Summary . . . . .   | 10   |
| II. REVIEW OF LITERATURE . . . . .  | 11   |
| History of Skin Grafting . . . . .  | 11   |
| Autografting . . . . .  | 11   |
| Homografting . . . . .  | 12   |
| Heterografting . . . . .  | 13   |
| Advantages, Uses, and Disadvantages<br>of Homograft and Heterograft . . . . . | 14   |
| Advantages . . . . .  | 15   |
| Uses . . . . .  | 28   |
| Disadvantages . . . . .   | 31   |
| Comparison of Pigskin Preparations . . . . .                                  | 35   |
| Processing pigskin . . . . .  | 36   |
| Viability . . . . .   | 42   |
| Affect of pigskin on the wound . . . . .                                      | 48   |
| Immune response . . . . .   | 48   |
| Histologic evaluation . . . . .   | 50   |
| Use of the various forms . . . . .  | 51   |
| Wound Healing . . . . .   | 52   |
| Mechanisms of healing . . . . .   | 53   |
| Vascularization of grafts . . . . .   | 58   |
| Immune response stimulated by pigskin. . . . .                                | 61   |
| Wound Management . . . . .  | 66   |
| Objectives of wound care . . . . .  | 66   |
| Heterografting procedure . . . . .  | 69   |
| Care of grafted wounds . . . . .  | 72   |
| Summary . . . . .   | 74   |



|   | Page |
|---|------|
| III. PROCEDURE FOR COLLECTION AND TREATMENT OF DATA | 76   |
| Setting   | 76   |
| Population  | 77   |
| The Tool  | 78   |
| Procedure for Collection of Data                    | 79   |
| Procedure for Treatment of Data                     | 82   |
| Summary   | 82   |
| IV. ANALYSIS OF DATA                                | 83   |
| Bacteria Levels                                     | 84   |
| Adherence   | 86   |
| Number of Applications Required                     | 87   |
| Inflammation - Clinical Evaluation                  | 89   |
| Healing Time  | 89   |
| Histologic Evaluation                               | 91   |
| Summary   | 91   |
| V. SUMMARY, CONCLUSIONS, IMPLICATIONS AND           |      |
| RECOMMENDATIONS                                     | 94   |
| Summary   | 94   |
| Conclusions   | 96   |
| Implications  | 96   |
| Recommendations                                     | 98   |
| LITERATURE CITED                                    | 101  |
| BIBLIOGRAPHY  | 106  |
| APPENDIX  | 115  |

## LIST OF TABLES

|   | Page |
|---|------|
| 1. Demographic Data . . . . .                           | 84   |
| 2. Cultures . . . . .                                   | 88   |
| 3. Adherence of Heterografts on Subsequent Visits . . . | 89   |
| 4. Number of Heterograft Applications . . . . .         | 89   |
| 5. Clinical Inflammation on Subsequent Visits . . . .   | 90   |
| 6. Time for Complete Healing . . . . .                  | 93   |

## CHAPTER I

### INTRODUCTION

Pigskin is being used by many physicians as a biologic covering for open wounds. Studies have proven that the skin promotes healing and patient comfort. It may be obtained in one of four forms: fresh, frozen, lyophilized (freeze-dried), and frozen irradiated. However, the question remains whether each of these forms promote healing in the same way. Numerous animal studies have been conducted to compare the various forms, but as yet it cannot be stated how each affects healing of burn wounds in man. It is possible that varying circumstances (various amounts of bacterial colonization, the condition of the burn wound surface, or the application technique required) may influence the value of the different forms.

In this study, several of these relationships were investigated so that necessary procedures for nursing management of pigskin grafts could be more clearly delineated. Through findings of this and future experiments, insight into the nature of healing beneath fresh and lyophilized porcine skin heterografts will be gained and better use of each of these preparations may be employed.

#### Statement of Problem

The problem of this study was to compare healing responses of human burn wounds to treatment beneath viable and non-viable pigskin heterografts.

### Purposes

The purposes of this study were:

1. To determine the healing process of burns beneath fresh porcine heterografts as measured by healing time and histologic response.
2. To determine the healing process of burns beneath lyophilized porcine heterografts as measured by healing time and histologic response.
3. To compare the healing processes of burns beneath fresh and lyophilized porcine heterografts as measured by healing times and histologic responses.

### Background and Significance

The goal of all who manage the care of burned patients is to convert the contaminated open wound to a clean closed wound in the shortest possible time (Wood 1972:720). This is often accomplished by the use of a variety of skin grafts. "Isografts" are tissues from an identical twin; "autografts," are tissues from one's self. Grafts taken from a blood relative, a non-related donor, or a cadaver, are usually termed "allografts" or "homografts." "Heterograft" is usually used to indicate tissue from an animal or different species; whereas "zoograft" and "xenograft" may refer to any foreign tissue, usually an animal (Wood 1972:721). Homografts and heterografts are valuable as coverings for a large open wound when it is not ready to accept autograft, or autograft is not readily available (Baxter 1970:2; Switzer 1966:398).

The Burn Treatment Skin Bank explained that interest in pigskin as a biologic dressing developed because of "... its ready availability, gross architectural similarity to human skin, and sparse distribution of hair. Though microscopically dissimilar from its human counter-part in several respects, porcine skin is markedly similar in texture and ability to adhere to open wounds" (1973:1). Bromberg stated an added advantage in using pigskin is for the technical ease in obtaining split-thickness skin from the wide, tense body surface. He also found these animals to have a relatively rapid re-epithelialization of skin so repeated crops could be obtained from the pigs in a short period of time (Bromberg 1965:81).

Porcine skin may be purchased fresh, lyophilized, fresh frozen, or frozen irradiated. The fresh skin is stored at 4°C. and shipped via Air Mail Special Delivery, usually less than twenty-four hours after processing. An expiration date is on the label, and its usage is recommended within fourteen days. Lyophilized or freeze-dried porcine skin is sterilized by gamma radiation and packaged in a sterile dry-nitrogen atmosphere. This type of skin may be stored at the burn center up to one year at room temperature. To be fully reconstituted, it must be placed in a balanced salt solution for a minimum of twenty minutes prior to use. Fresh frozen porcine skin may be stored up to three months at or below minus 18° C. It should be thawed quickly in a solution at or above room temperature, but no higher than 37° C. Once thawed, it may be stored at regular

refrigerator temperatures up to seven days. It should never be refrozen. Finally, frozen irradiated skin is handled in the same way as frozen skin, except that it may be stored indefinitely at minus 78° C., and for 6 months at minus 18° C. (Burn Treatment Skin Bank 1970:4-5; Wood 1972:720).

Grafts, in particular xenografts, are widely used for a number of reasons. Primarily, grafts obtain closure of an open wound (Pruitt 1971:398). This, in turn decreases pain (Baxter 1970:3; Rappaport 1970:144) and helps prevent and control infection (Pruitt 1971:397). Eade found that "coverage with fresh viable or preserved nonviable autografts or homografts permits the granulation tissue to destroy surface bacteria rapidly" (Wood 1972:722). "On bacteriologic studies, Rappaport, Pepino, and Deitrick found, except in severe burns, that the material beneath the pigskin remains sterile for as long as three weeks" (Wood 1972:721). According to Rappaport, porcine heterografts enhance the process of eschar separation; eschar separation begins in eight to ten days and is complete in twenty-one days when covered with pigskin, but without pigskin eschar begins separation at about the third week, and is not complete for four to five weeks (1970:145). It is used by many surgeons to "clean up" a wound for surgery, or in other words, to elicit the final debridement of the dermal debris (Baxter 1970:2). Pigskin covering promotes a more pliable eschar (Rappaport 1970:146) and greater range of motion (Wood 1972:722).

Porcine heterografts have been found to restore the water-vapor barrier and inhibit protein losses in wound exudate. With such a skin cover, the catabolic response is reversed and the patient therefore gains weight, eats and moves better, has an improved mental outlook, and generally, becomes a better operative risk (Baxter 1970:3). Also, with skin covering, a stability of core temperature may be maintained (Rappaport 1970:146). Observations made by Moncrief and Miller indicated that biopsies taken from partial-thickness burn wounds within twenty-four hours post-grafting showed reduced edema and inflammation in burns covered with pigskin than in burns which healed uncovered. This healed tissue also exhibits normal maturation and polarity. On the other hand, in the uncovered area, there was disorganization in normal maturation from the prickly cells to the other cells, and the cells lost their polarity (Miller 1967:122; Wood 1972:721). Morris, Bondoc and Burke speculated that the graft has a direct organizational effect on the wound healing mechanism (1966:17).

Pigskin is placed over the wound in a sterile procedure with the dermal side against the burned tissue, and then smoothed down to remove all air pockets. Adjacent sheets should be contiguous to prevent desiccation of exposed granulation tissue. Sutures are not needed; dressings may or may not be used (Pruitt 1971:400). Its use may be combined with topically applied antibiotics (German 1972:806), or in conjunction with autograft until there is enough of the patient's own skin to cover the wound (Baxter 1970:3).

It is usually changed every one to two days, but if daily inspections reveal no purulent material beneath the graft, it may be left in place for the optimal four days (Baxter 1970:3). Rappaport stressed, "we're not discussing a graft in the real sense, we are rather talking of a dressing. We are talking of twenty-four hour applications, we are not talking of a week at a time" (1970:127). If the graft is left in place for a long time it will reject after a few weeks and cause excessive scarring (Artz 1972:936).

Bromberg and Song conducted studies on mice to compare the healing of burns beneath freeze-dried split-thickness skin and fresh skin. Their results showed that in the first two weeks the freeze-dried grafts remained soft and little inflammatory response could be observed. Gradually, however, the grafts became dehydrated and were autolyzed in the next few weeks. Histologically, there was no evidence of vascularization or cellular infiltration. "These results are similar to those obtained earlier with fresh pigskin" (Bromberg 1965:85). Rappaport compared frozen irradiated and fresh skin on dogs and found that "in short term application, the frozen irradiated porcine skin was as effective histologically as fresh porcine" (1970:144).

Pigskin is applied painlessly by the nursing staff. Nurses are also responsible for evaluating the wound and determining if the skin needs to be removed at dressing changes. Only by understanding tissue's normal reaction to the pigskin can pertinent



observations be made about the wound's healing with the necessary judgments in planning nursing management.

### Hypotheses

For the purpose of this study, the hypotheses were:

1. There is no difference in healing time of burns being treated with fresh pigskin when compared with those wounds treated with lyophilized pigskin heterografts.
2. There is no difference in histologic response of burns treated with fresh pigskin when compared with those burns treated with lyophilized pigskin.

### Definition Of Terms

Throughout the discussion of this research, the following terms were used:

1. Homograft (or allograft) - skin taken from an animal of the same species, but having a different genotype.
2. Heterograft (or xenograft) - skin taken from a species different from that of the recipient.
3. Pigskin (or porcine skin) - the type of heterograft which will be used in this study to cover burn wounds.
4. Fresh Heterograft - pigskin which has been processed and maintained at 4° C.
5. Lyophilized Heterograft - pigskin which has been preserved through a freeze-drying process.

6. Histologic Response - cellular response to treatment observed microscopically as measured by inflammatory response and epithelial coverage.
7. Histologic Inflammatory Response - response of tissue to injury and/or treatment as reflected microscopically by migration of leukocytes and lymphocytes, and changes in vascularity.
8. Gross Inflammatory Response - gross response of tissue to injury and/or treatment as indicated by heat, pain, redness, and swelling.
9. Rodac Culture - a contact plate culture, applied directly to the wound surface.
10. Adherence - the collagenous bond between the wound and the graft.

#### Limitations

The following limitations were recognized as a part of this study:

1. Patients do not always keep appointments with physical therapy as instructed.
2. Patients do not always care for wounds at home as instructed.
3. There may be some degree of variance in wound depth.
4. The immunologic response to heterograft varies with individuals.

5. The bacterial content within the burn wound may vary.
6. The patient may have another disease process occurring which affects the response to the healing process.

#### Delimitations

The following delimitations were established:

1. All patients used in the study were between ten and sixty-five years of age.
2. Patients with second degree burns covering between 3 and 20 percent of the total body surface area were used for the study.
3. All persons used were out-patients who came for physical therapy a minimum of three times a week.
4. All patients had burns other than on the face and areas which preclude biopsy.
5. All patients will be free of allergy to porcine products.

#### Assumptions

This experiment was based on the following assumptions:

1. Skin reduces gross evaporative fluid loss.
2. Skin minimizes bacterial infection.
3. The inflammatory response to subcutaneous injury is decreased with the application of skin coverage.
4. Skin coverage is important to wound healing.

### Summary

Through the use of a variety of types of skin grafts a contaminated open wound may be converted to a clean closed wound. Pigskin heterografts, used as biological dressings, have been proven to effectively provide closure of wounds and promote healing of second degree burns. The problem of this study, is to compare healing times and histologic responses of human burn wounds to treatment with two preparations of pigskin (fresh and lyophilized) in order to make some comparisons as to how each affects the healing process.

In Chapter II, the literature pertaining to heterografting as it relates to wound healing will be reviewed. Chapter III will discuss the method used to obtain the burn patient population, the procedure used in applying the two types of pigskin, and the method by which data on the progress of the wounds' healing was collected. Analysis of the data collected through gross observations of the healing wounds, and histologic responses as determined by biopsies will be presented in chapter IV. Chapter V will present conclusions and recommendations based on data analysis of the responses of wounds to fresh and lyophilized pigskin heterografts.

## CHAPTER II

### REVIEW OF LITERATURE

Throughout the years, persons suffering trauma with massive skin loss have posed a special problem to the surgeon. Without adequate wound coverage, healing progressed slowly and infectious organisms proliferated rapidly. Many of these cases proved fatal. Eventually trial and error revealed that tissues taken from one individual and applied to another resulted in improved wound healing. The use of animal tissues likewise promoted patient well-being.

In this chapter, the history of skin grafting, as well as some of the advantages, uses, and disadvantages of the application of biologic dressings will be explored. Discussion on the various types of pigskin heterografts, the nature of wound healing, and the method of wound care will follow.

#### History of Skin Grafting

##### Autografting

The first reference to skin grafting dates back as far as 750-800 B.C. when Sushruta, the father of Hindu surgery, wrote of the advancement of a cheek flap to reconstruct a nose. It was not until the 1800's that autografting was studied in depth. Originally used primarily for reconstruction, Leroux reported in 1817 the

formation of a nose taken from the buttocks. Twenty-seven years later, Pancoast used autograft tissue in reconstructing an ear lobe. Reverdin was one of the earliest users of skin grafts, and is noted for his thin "pinch" grafts in 1869. In 1872, Ollier de Lyon expanded this technique and began employing sheets of epidermis four to eight centimeters square for autografting. At the Fifteenth Congress of the German Surgical Association in 1886, Thiersch reported his success in skin grafting large sheets of thin, split-thickness skin. These grafts are now correctly referred to as "Ollier-Thiersch" grafts, or often simply "Thiersch" grafts. In 1875 Wolfe further expanded this technique by introducing full-thickness autografts, later popularized by Feodor Krause in 1893. Full-thickness autografts today may be referred to as "Wolfe-Krause" grafts (Rogers 1959).

#### Homografting

Homografting dates back to 1503 when Elisia Galenzio wrote of seeing Banco of Sicily give a person a new nose which he "borrowed" from a slave. In 1872, Reverdin makes reference to clinicians using skin from amputated limbs and cadavers (Rogers 1959), and in 1881, Girdner at Bellevue Hospital in New York, reported the use of post-mortem skin on full-thickness burns (Pruitt 1971:1537). His aim, however, was for long-term acceptance of the skin by the recipient, and the problem of rejection limited its use (O'Neill 1973: 705). Even early writers noted the rejection phenomena, believing that when tissue was donated to another individual, that tissue would

die when the original owner died. Development of the Padgett-Hood dermatome in 1939 made the homografting procedure faster and more feasible (Rogers 1959). In 1966, Zaroff and Moncrief described the beneficial use of cadaver skin as a temporary wound cover in extensively burned patients (O'Neill 1973:705).

### Heterografting

Xenografts were referred to in 1682 in Observationes Medico-Chirurgicae, by Jobus a Meekren who related the story of a nobleman whose head had been cleft by a sword, requiring repair with a piece of canine skull (Artz 1972:934). In the same year, Canaday experimented with the application of water lizard skin to human wounds (Pruitt 1971:1537). In 1872 and 1877, respectively, records were made of rabbit skin being used as a covering for leg ulcers, and pigskin being used by Ravin to cover a burn wound. In his textbook on plastic surgery, published in 1919, John Davis described the use of xenografts from a wide variety of animals and fowl, including rats, rabbits, young puppies, guinea pigs, pullets and pigeons (Rogers 1959:308). In the United States, the first attempt at heterografting was made in 1880 by Dr. E. W. Lee of Boston in treating extensive burns with skin flaps from sheep (Artz 1972:934). In 1930 Loeb recognized that strain, species, generic, and class differences prevent long-term viability of homografted organs, and conclusively demonstrated the ultimate rejection of long-term homograft and heterograft (Pruitt 1971:398).

In 1949, Silvette proposed the temporary use of bovine embryo skin on human wounds (State 1974:13) and in 1965 Bromberg, Song, and Mohn reported the use of pigskin as a temporary biological dressing in burned patients (1965:80). By 1969 the advantages of pigskin were well documented and the Burn Treatment Skin Bank, Inc. of Phoenix, Arizona made its first shipment of commercially produced fresh porcine skin. Within the next three years pigskin was commercially available in three additional storage forms -- fresh frozen, frozen irradiated, and lyophilized (freeze-dried) -- and is currently being shipped to burn units throughout the United States and abroad (Burn Treatment Skin Bank 1973:1).

Advantages, Uses, and Disadvantages  
of Homograft and Heterograft

Shuck has defined three factors which should be characteristic of any material used to cover large open wounds. "Such a substance would of necessity provide the following: 1) control of bacterial growth, 2) a means to prepare and preserve the wounds for definitive closure, and 3) effective vapor and exudate barrier" (1969:472). Homograft and heterograft has been shown to meet the above criteria and their effectiveness has been documented by many prominent surgeons. Artz summed up the uses of biological dressings on open wounds for the following purposes (Artz 1972:937):

1. Debride granulating areas
2. Protect open wounds from water and protein losses



3. Decrease pain
4. Increase mobility
5. Decrease bacterial counts
6. Enhance the growth of epithelium

Skin grafts may be utilized to temporarily compensate for defects in skin integrity in any number of conditions, including burns, trauma, infusion sloughs, circulatory ulcers, and congenital deformities (State 1974:13). However, in some burn units availability, expense, and the physician's preference may preclude the use of homografts and heterografts. This section will deal with the advantages and uses of biological dressings as well as some of the disadvantages to their use.

#### Advantages

At a meeting of the American Society of Plastic and Reconstructive Surgeons held in 1964, Bromberg, Song, and Mohn presented a paper on their research in the use of pigskin as a temporary biological dressing. They pointed out that an adult with a fifty percent full-thickness burn needs approximately six thousand centimeters of skin to obtain coverage. In a case such as this, autograft donor sites are few and a single living person cannot donate such a quantity of skin. Often several applications of homograft are required before the wound may be autografted. Homograft survival is limited, and the same donor cannot be used repeatedly if the accelerated rejection

of second-set grafts is to be avoided (1965:80).

"To avoid immune rejection in the critically ill burned patient, allograft skin is customarily removed and changed every two to five days. This large recurring demand can seldom be matched with the unpredictable supply of cadaver skin. The possibility of transmission of disease to recipients further limits donor availability. The time, personnel, and equipment necessary for allograft harvest are also limitations in most hospitals" (Pruitt 1971:1538).

For these reasons, it was necessary to investigate substitutes for human skin, and a closer look at materials from animal sources evolved (Bromberg 1965:80, Song 1966:576).

Baxter was one of the early users of heterografts in addition to homograft. In his address to the First Congress of the Society of German Plastic Surgeons in Munich, he stated that

"after the development of the technique of employing skin as a temporary biologic dressing, many applications rapidly evolved. The demand for cadaver skin became excessive. Experimentation with various animal skins led to the realization that porcine heterograft could be employed almost as effectively as cadaver homografts for the same purposes" (1970:1).

The selection of White Yorkshire pigs as skin donors was made after experimentation with a variety of animals. Bromberg noted that 1) pigskin has close structural similarity to human skin, 2) there is a sparsity of hair as compared to the skin of other animals, 3) there is a readily available unlimited supply, 4) there is technical ease in obtaining split-thickness skin from the wide and tense body surface, and 5) repeated crops of skin in a short period of time are available due to the rapid re-epithelialization of skin (1965:1607). According to Moncrief, the skin of the blond pig is preferred because its optical properties allow more accurate evaluation

of the underlying wound (1973:450). Song has added that pigs are desirable donors because "pigs skin closely resembles human skin and can therefore achieve temporary cosmetic repair," and pigs "can be maintained within many laboratories or can be readily obtained" (1966:582). Histologic studies on fresh porcine xenografts reveal that the structure of porcine skin "is not greatly affected by the processing procedure nor does it differ much as a function of location. The skin from the snout or legs is different, but the region from which xenografts are taken (i.e. the torso) is similar from point to point" (Bertke 1972:7).

In actual use on patients, pigskin xenografts proved to be applied easily and to conform readily to uneven wound surfaces (O'Neill 1973:706). Bromberg found that pigskin is generally devoid of any local rejection reaction and originally does not manifest any adverse systemic response (1970:1645). In considering time and expense in obtaining fresh cadaver skin as compared to porcine skin, Baxter calculated that

"the cost of obtaining heterograft was not dissimilar to that of obtaining homograft. However, the development of commercial facilities (Burn Treatment Skin Bank, Inc., 2430 East Washington Street, Phoenix, Arizona, 85034) for furnishing fresh heterograft, stored for less than twenty-four hours prior to delivery, furnishes an economical and time-saving means of clinically employing the principles of the use of skin as a biologic dressing" (1970:2).

The advantages of using biologic dressings have been documented by numerous physicians for a variety of purposes. One such purpose

lies in the application of biologic dressings to debride a wound and to prepare it for grafting (Miller 1967:117, Artz 1972:937).

Baxter described this use in more detail, stating that

as soon as separation of the thick eschar is progressing, heterografts can be used on granulation surfaces adjacent to the eschar and for the final debridement of dermal debris after the separation of most of the necrotic tissue. Unfortunately, all of the wound seldom cleans up at one time so that many grafting procedures are necessary for wound closure. With repeated applications of heterograft, definitive surgery for autograft coverage can be delayed until the repeated application produces an ideal bed over the entire burn surface (1970:2).

Wood noted that "frequent changes of the xenograft provide an atraumatic debridement of the wound and prevent exudative and necrotic tissue accumulation" (1972:722). According to Shuck,

when homografts are changed as exudate and dermal debris accumulate beneath the skin, debridement is effected with the removal of the covering. In this way, the tissue bed is prepared by removing debris, by diminishing edema in the wound, and by encouraging healthy granulation tissue to form (1969:473).

In carrying this concept of using biologic dressings to "clean up" a wound one step further, it has been found that the adherence of homograft or heterograft to granulation tissue may be used as an indication that the wound will accept autograft. In using homograft over granulating surfaces with small bits of adherent nonviable debris, Hunt observed that subgraft purulence may be seen in areas of remaining dermis, necessitating daily graft changes.

Subgraft suppuration decreases as the wound bed matures and subsequently applied allograft skin may remain in place for up to three to five days. A wound 'tested' with homograft

is ready for autografting when the homograft is adherent to the entire wound, and when removal of the allograft results in active bleeding from the 'granulating' bed (1973:693).

Shuck described completion of the debridement process when homograft "takes." At this point, homograft is adherent to the underlying bed, it blanches with pressure, and no debris or purulent material may be noted accumulating beneath the graft. When the "take" has occurred the wound is ready for permanent autograft coverage.

In summary, Shuck wrote

homograft skin is an excellent 'test' material to predict the receptiveness of granulation tissue to autograft. When homograft has 'taken' well with no exudate beneath it, autograft success should approach one-hundred percent (1969:474).

Clarification of the term "take" is necessary at this point.

Pandya and Zarem emphasized that the term "take" has been used loosely among clinicians suggesting vascularization of the heterografts, whereas actually the heterografts seem to lie inert on the burn surface.

"The adherence of the skin heterografts and the appearance of a pink hue under them have frequently been considered evidence of a 'take', but are likely the effects of a fibrinous adherence between the graft and underlying wound" (1974:213). On the other hand, Miller, Switzer, Foley, and Moncrief noted that application of homografts to the wound resulted in grafts becoming pink and blanching with pressure forty-eight to ninety-six hours after application. The graft became progressively more adherent and removal after five days was associated with considerable hemorrhage from the recipient site, whereas prior

to this time the homograft could be removed without bleeding. This change they believed, indicated homograft circulation (1967:118). Additional mention of this vascularization concept will follow in the discussion on wound healing beneath grafts.

Biologic dressings also serve as a protection on open wounds in decreasing water and protein losses. Artz has written that unlike an absorptive dressing, the biological skin dressing seals the wound and inhibits the loss of water and protein (1972:936). Wood (1972:722), Pruitt and Silverstein (1971:1538) have found that the biologic cover decreases water, electrolyte, and protein loss. This in turn decreases heat loss due to evaporation and minimizes energy requirements of the patient. Shuck stated that an advantage of the application of biologic dressings is the prevention of water and protein losses. "This decreases the caloric expenditure and will reverse the catabolic state diminishing the energy drain" (1969:474). Baxter observed that in restoring the water vapor barrier, decreasing the protein losses in wound exudate, and protecting the wound from infection by applying biologic dressings, a much less significant weight loss resulted in most patients (1970:2).

The use of biologic dressings decreases pain (Miller 1967: 117; Pandya and Zarem 1974:212) when applied as a second degree burn wound covering. Chang (1973:149) and Graham (1971:498) recommended its use on donor sites where it "virtually eliminates all pain and discomfort." Baxter has recognized that when pain of the open wound

is relieved, aggressive active physiotherapy may be tolerated by the patient, thus maintaining or restoring function to all mobile parts of the body (1970:2). The benefit of active joint motion when pain is minimized (Moncrief 1973:450) is particularly impressive in maintaining hand function (Shuck 1969:473). Wood stated that "reduction of pain is remarkable, and because of this and the great reduction in the bulk of dressings, motion and ambulation are better and joint motion is encouraged" (1972:722). Young has observed that

when early coverage of burn sites by homografts was accomplished over areas of flexion and extension, there seemed to be fewer contractures occurring at these sites. This was probably related to the ability of the patient to move these joints without overwhelming pain, thus encouraging early institution of active and passive joint motion (1960:44/212).

The fact that biologic dressings decrease bacterial counts has received much discussion. The leading cause of death in hospitalized burned patients throughout the world is infection. Teplitz and others studied the pathogenesis of burn wound sepsis, identifying the burn wound as the primary source of sepsis. The wound surface was shown to be relatively sterile for three hours following thermal injury, but soon became more heavily contaminated by organisms from the patient's own flora, the surrounding environment, and the attending personnel. Early sepsis was seen as wound colonization, which progressed to bacterial invasion of viable adjacent tissue. This progression occurred in several identified stages. Initially, bacteria was localized to hair follicles. In the untreated burn,

this stage was followed by superficial invasion into the avascular, nonviable eschar by the third or fourth day postburn. At this stage, gram-positive organisms predominated, but within a week gram-negative organisms dominated the wound. Late in this stage, heavy bacterial penetration was noted throughout the eschar with proliferation at the viable-nonviable interface. By the fifth postburn day, the bacteria invaded the zone of viable granulation tissue. Finally, the bacterial invasion destroyed the granulation bed and entered deeper viable tissues, including the blood stream (Teplitz 1964:202-4; Hunt 1973:690; Nathan 1973:71).

Findings by many physicians indicate that biological dressings in some way decrease the bacterial count within burn wounds. Pandya referred to a reduced bacterial count in granulating tissue following homografting and heterografting (1974:212), and Bromberg reported that pigskin "exerts a beneficial influence upon the wound surface, with a reduced bacterial population" (1966:31). German and co-workers reported that "xenograft dressings seemed to reduce infection in contaminated wounds. It has been theorized that xenograft dressings possess special properties which decrease infection and promote healing" (1972:806). Wood summarized the effects of pigskin in preventing sepsis. He pointed out that with the application of such a dressing, the wound is closed to invasive infection and contamination is decreased. In addition the material beneath the pigskin remains sterile for as long as three weeks (1972:721). Moncrief added that the graft



allows active phagocytosis of bacteria beneath its protective covering and that by twenty-four hours post-application of homograft a granulating surface's viable bacteria count is reduced by ninety percent (1973:450).

In 1973, Nathan, Holder, and MacMillan raised the unresolved question of how skin grafts reduce bacterial numbers in infected surface wounds and listed some theories which have been suggested as this mechanism. Two possibilities are that an antibacterial factor is present within the graft or that closure of the wound permits the host to rid the wound of bacteria (Nathan 1973:71). Studies by Eade on patients with granulating, infected burn wounds seemed to suggest the latter. He found a reduction in wound bacterial levels over a twenty-four hour period after graft application. This reduction in cell count occurred both beneath viable autografts and allografts, and beneath nonviable, lyophilized skin grafts. For this reason he concluded that bacterial reduction was a function of the granulation tissue itself; the graft merely providing a protection for the underlying granulation tissue (Eade 1958:55). On the other hand, Sewell's experiments with freeze dried grafts indicated that they were only effective as a temporary wound cover in areas free of bacterial contamination (Sewell 1956:360). Other researchers suggest that the elimination of wound exudate within which bacteria proliferate readily may be a portion of the answer (Nathan 1973:71).

Morris, Bondoc, and Burke have looked at the use of frequently changed skin allografts to promote healing in the nonhealing infected ulcer. They described their results as "impressive." One factor which became evident was the antibacterial effect of graft application, but they stated that "the exact character of this antibacterial effect is not clear." They suggest the possibilities that there is an intrinsic antibacterial activity in the interstitial fluid of the graft, or that the immune response generated by the graft is, in itself antibacterial. However, these theories were dismissed on the basis that the same donor skin was never in place more than six days, and histologic examination of the ulcer bed on removal of the grafts showed no rejection phenomenon. Their hypothesis that the observed antibacterial effect lies in the biologic closure of an open wound, thereby preventing further bacterial contamination and allowing the host's own defense mechanisms to deal with the infection, correlated more closely with their findings (1966:18). Saymen and others observed through rat studies that skin grafts placed on the surface of wounds freshly contaminated with Pseudomonas aeruginosa lowered the bacterial count within two hours, with a second decrease occurring between four and twenty-four hours after grafting. Histologic studies of contaminated exposed muscle revealed a leukocyte migration from the muscle surface to its base. After skin graft coverage a reversal took place, and the white cells

moved toward the surface of the muscle. They state,

it is suggested that this alteration in cell movement after graft application might modify the white cell function and result in a greater bactericidal activity. Apparently grafts lower bacterial levels in an established infection by modifying the host response to the surface contamination (1973:921).

Burleson and Eiseman have also produced a study of the mechanisms by which partial thickness skin wound dressings affect antibacterial activity. The effect of various types of skin on bacterial counts of infected wounds was analyzed in 142 rat experiments. They noted that sterilization of granulation tissue preceded disappearance of bacteria on the wound surface. In addition, they found that skin viability was not essential for the antibacterial effect of the biologic dressing to result. The skin dressings caused a slight ( $2.1^{\circ}$  C.) increase in wound temperature and a decrease of 0.007 units in alkalinity beneath the graft which possibly improved phagocytosis but did not significantly alter bacterial growth. Finally, it was found that adherence of the biologic dressing to the underlying contaminated wound bed was invariably associated with subsequent wound sterilization, and they suspected a casual relationship (1973:185).

From these studies it is clear that in some way, homograft and pigskin heterograft impose a bacteria reducing function on an open wound. Though the specific mechanism by which this effect occurs is presently under study, it is known that biologic dressings do protect the wound and the patient from sepsis (Baxter 1970:2), is

useful in preventing recolonization of a wound (Polk and Stone 1973:315), and can act to sterilize an infected wound (Burleson 1973:185).

An additional advantage to the use of biologic dressings on open wounds, is that they seem to enhance the growth of epithelium (Artz 1972:937). As Shack states, "In partial-thickness burns, reepithelialization takes place beneath the homograft at such a rate that it appears that the skin is 'stimulated' to regenerate" (1969:473). In comparing heterografts with homografts Mast writes, "These grafts (porcine) have the same power of stimulating epithelial growth from the edges when placed on granulating wounds" (1972:1). Hunt (1973:693) and Moncrief (1973:450) also both mention the clinical evidence that pigskin stimulates the rapid growth of epithelial islands and granulation tissue.

Elliott and Hoehn have taken the biological dressings' effect on healing one step further. They stated that

The epithelial explosion initially noted beneath autogenous split-thickness grafts is also observed with porcine skin grafts. This phenomenon restores nearly normal skin architecture in superficial burns or wounds and promotes closure in the deeper one (1972:401).

Pruitt and Silverstein also commented on the quality of healing beneath temporary skin dressings. Reported findings indicate that not only was healing hastened, but also "improved," with a more differentiated epidermis and mature dermal collagen (1971:1538). Through its ability

to minimize dehydration, Zawacki pointed out that porcine skin treated burns showed no necrosis, full reversal of capillary status, return of hair follicle epithelium to histologic normalcy, and full epithelial resurfacing by the seventh postburn day (1974:101).

Used on donor sites, pigskin has been found to have similar effects. Baxter reported in 1970 that heterografts decreased the healing time of donor sites by approximately one-third. In addition, "the incidence of infection and hypertrophic scarring in donor sites is almost completely eliminated" (1970:4). Chang's experimentation with reconstituted lyophilized pigskin dressings on skin graft donor sites showed that by minimizing the inflammatory reaction around the donor sites, pigskin allowed epithelialization to proceed at an earlier date. Earlier maturation and organization of the epithelium's basal layers was also seen (1973:149).

Finally, a general sense of well-being in numerous patients may be attributed in part to the use of pigskin heterografts and homografts. The xenografts are applied without anesthesia or suturing, adhere readily, and require minimal or no dressings (Wood 1972:722). Baxter observed that during the period of skin cover, the catabolic response is reversed, the patient gains weight, eats well, moves better, and develops an improved mental outlook. He therefore also becomes a better operative risk (1970:3). Young described patients treated with homograft as gaining a general over-all improvement, as evidenced

by a consistent and persistent fall in the temperature of the patient, decrease in pain with a diminished amount of sedation required, and a general feeling of well-being (1960:44/212). According to Wood, the general psychological attitude of the patient is greatly improved with a concomitant increase in appetite and sense of well-being (1972:722). After treating 160 thermally injured patients with porcine dressings Wood and Hale summarized their findings:

It is our observation that the use of temporary biologic dressings lessens morbidity of burned persons, improves survival, shortens rehabilitation, and is an acceptable method in the management of the burned victim (1972:723).

#### Uses

The use of pigskin heterografts is routine in caring for burned patients. As mentioned previously, it may be used as a cover over partial thickness burn wounds, or as a temporary dressing following excision of full-thickness eschar (Wood 1972:721, Hunt 1973:693). "Patients requiring skeletal traction also can be effectively treated since this technique requires no dressings" (Shuck 1969:747). In a paper on Care of the Burned Ear, Irene Robbins of Phoenix, Arizona recommended the use of pigskin dressings to diminish pain, reduce oozing of fluid, and decrease swelling. "The dressing protects the underlying cartilage and decreases bacterial contamination. It also maintains a softer texture of the skin, and aids recovery by minimizing the potential of chondritis." Some physicians utilize

lyophilized pigskin on donor sites to eliminate pain and discomfort, allow earlier ambulation with comfort, and minimize the inflammatory reaction (Chang 1973:149).

Artz (1972:937) recommended the use of porcine xenografts for:

1. Preparation of recipient sites for grafting
2. Treatment of leg ulcers and decubitus ulcers
3. Second-degree burns
4. Cover for mesh grafts
5. Protection for large open wounds until autografts are available.

Biologic dressings are also used to cover viable structures, temporarily protecting nerves, vessels, bone, cartilage and tendon (Hackett 1974:427, Pruitt 1971:1538, Wood 1972:722). Ledgerwood advocated the use of porcine skin to cover exposed vein grafts. She wrote,

It was noted during the dressing changes that a thin gray, mucoid-like layer of serum remained on the exposed vein graft after the pigskin was removed. This thin mucoid layer appeared to protect the exposed vein graft from the microdebridement, which typically accompanied the removal of fine mesh gauze from the remainder of the wound. During the course of therapy, pink islets of granulation tissue appeared within this mucoid layer and gradually coalesced until the entire vein graft was covered by granulation tissue. Autografts were then applied (Ledgerwood 1973:203).

Graham (1971:501) recognized the variety of situations in which biologic dressings may be used beneficially. He lists these situations as follows:

1. Thermal injury
2. Chronic wounds
3. Index of wound preparation
4. Contaminated open wounds
5. Protection of split-thickness donor sites
6. Coverage of fresh traumatic wounds
7. Temporary dressings in pedicle flap donor areas

Elliott and Hoehn have experimented with the use of commercial porcine skin in the treatment of open wounds. In addition to protection of partial thickness injuries, stasis ulcers, and donor sites, they recommended that pigskin dressings may be utilized to treat patients with avulsions of the nail. Pigskin protected the exposed nailbed, relieved pain, and adhered to the area until it was pushed off by the advancing nail (1973:403). Baxter has found that use of heterografts on large open soft tissue traumatic wounds, such as those occurring in association with fractures, surgical infections, and wounds requiring delayed primary closure techniques effectively decreased the time required for preparing these wounds for closure (1970:4).

In 1974, State and Peter published an article on "The Clinical Uses of Porcine Xenografts in Conditions Other than Burns." In this publication, they cited the use of pigskin to cover surgical wounds following radical debridement as an alternative to amputation of a limb, and porcine heterografts to protect the area surrounding



an ileostomy where the skin had retracted and abscesses had formed. A third case study reported successful healing of a fifteen year old indolent ulcer associated with sickle cell disease, following the application of porcine dressings. Finally, the case of a non-functioning ileostomy and infected laparotomy incision was treated by placing fresh pigskin xenograft over the intestine until the site cleaned up and granulation tissue began to form. The authors recommended, "Porcine skin grafting is a technique that should be considered and tried whenever a difficult problem of tissue loss coverage and repair faces the surgeon" (State and Peter 1974:14-15).

#### Disadvantages

Biologic dressings may prove useful in a wide range of surgical situations due to their numerous beneficial effects; but their use is not without some disadvantages and cautions. Pruitt feels the major limitations of viable cutaneous homograft are those problems related to availability and storage. He lists these limitations as follows (1971:409):

1. Limited shelf life.
2. Requires refrigeration
3. Possible transmission of disease, such as hepatitis.
4. Converts third-degree burn to a closed "infected" wound when applied to eschar

5. Elevation of patient's core temperature has occurred immediately after grafting
6. Supply seldom matches demand

Lyophilized homograft also has several problems inherent in its processing, according to Pruitt. He has written, "Unless the skin to be lyophilized is taken at an appropriate thinness, the thicker lyophilized homograft is liable to dermal-epidermal separation with prompt desiccation of the exposed dermis and early sloughing from the covered wound." Pruitt has also observed that with this preparation there is less adherence to the wound, higher wound bacterial count after removal, and greater expense of processing, when compared with fresh homograft (1971:412).

Moncrief has noted that in some patients, application of biologic dressings to a wound is heralded by "a marked hyperpyrexia which responds only to the removal of the graft." He stressed that this reaction may occur with the initial application of the dressing, and should not be confused with a second-set reaction (1973:450).

Moncrief and Baxter have explained the seriousness of allowing homograft to remain in place until the patient responds with a rejection reaction. The patient, though originally protected and improved, becomes extremely ill systemically during this period of rejection (Moncrief 1973:450), which may take place for a few days up to several weeks. Systemically, the rejection response

is characterized by fever, gastrointestinal dysfunction, tachycardia, and extreme irritability and anxiety. At the site of the wound, edema and cellular reaction produce unhealthy granulation tissue, which will not take any type of skin during the rejection process (Baxter 1970:1). At this stage the patient is extremely vulnerable to bacterial invasion, sepsis and death. Therefore, to minimize the occurrence of this phenomenon, homograft should be employed only as a frequently changed biologic dressing (Baxter 1970:1, Moncrief 1973:450). Used in this way, the skin is removed before it may be rejected, and successive applications of homograft come from different donors thus delaying the onset of any type of rejection reaction (Baxter 1970:1).

Porcine heterografts have many of the same problems as homograft. In the literature produced by the Burn Treatment Skin Bank of Phoenix, Arizona, it is recommended that the following contraindications and precautions be observed when using pigskin dressings:

1. Porcine skin should not be used on patients with histories of multiple or serum allergies.
2. It should not be used over intact third degree eschar.
3. The grafted areas should be inspected every twenty-four hours to detect any purulent accumulations under the skin as soon as possible after they form. These areas should be cleansed and new skin applied.

4. If a rash unrelated to other therapy or systemic antibiotic therapy is observed, discontinue use.
5. Use of porcine skin on deep split-thickness skin donor sites should be used with caution as incorporation with delayed wound healing has been reported. No long-term negative sequelae have been reported.

When compared with homograft, porcine skin has been reported as less favorable in several respects. Hunt noticed that xenograft is more difficult to apply to the wound because of the variations in thickness and problems in its reconstitution from its lyophilized state (1973:693). In addition, Silverstein has written that while porcine heterograft provides adequate temporary coverage to clean, granulating wounds, it does not adhere as well as allograft to incompletely debrided wounds. Due to subgraft suppuration, an average of two or more graft changes for wounds treated with xenografts may be necessary (1971:2).

Through their use of pigskin in acute burns, Newsom, Salyer, and Baxter have reported that,

The disadvantages of porcine heterografts are mainly those of esthetics and its misuse. Porcine heterografts, as in any graft, must be observed daily for subgraft collections of serum, purulence, or necrotic tissue which should be removed. The heterograft must be removed and new pigskin applied at the maximum of every five days and more often if necessary. The exception to this is when heterografting areas of second degree burns when the porcine skin is left in place until separation occurs leaving a healed wound (1971:6).

At Brooke Army Medical Center, Salisbury and others conducted a study on donor site management on seventeen patients. Xenograft was

chosen as the biologic dressing rather than homograft because previous studies have suggested that pigskin does not establish direct vascular continuity with the host, yet functions effectively as a wound dressing. Six patients demonstrated abnormal healing of donor areas that had been covered with porcine xenografts. Their conclusions stated that, "Incorporation of porcine xenograft into the healing donor sites (as occurred in thirty-five percent of the patients in this study) makes such a technique of donor site care unacceptable" (1973:706).

Homografts and heterografts have been used successfully in the treatment of burns and other surgical cases. When used carefully biologic dressings have proven to be of value in promoting healing, mobility, and comfort of patients.

#### Comparison of Pigskin Preparations

Commercially, pigskin may be purchased fresh, frozen, lyophilized (freeze-dried), or irradiated. This section will compare how each of these forms is processed and stored. In addition, the literature pertaining to the viability of skin prepared in each of the above mentioned manners will be reviewed. Finally, studies on the effects of each type of skin when applied to wounds, in terms of its bond to the wound, the immune response provoked, histologic evaluation of wounds covered with different preparations, and suggestions for clinical use, will be considered.

### Processing Pigskin

Following the slaughter, of domestic swine at federally inspected sausage plants, clean hides are flown in refrigerated containers to commercial pigskin facilities. When received, they are treated with an iodophor surgical scrub solution, cut into strips and shaved. Split-thickness strips of skin are then removed with a Blair-Brown dermatome set at fifteen to twenty one-thousandths of an inch (Wood 1972:720). Following harvesting, fresh pigskin is soaked in an antiseptic solution (neomycin or iodophor solution) for several hours and thoroughly rinsed with sterile water. "In a sterile laminar air-flow chamber the skins are individually rolled over gauze, packaged, and doubly sealed and labeled in individual plastic containers" (Wood 1972:720). Routine culturing of the skin at different stages of the process assure bacteriologic control. Less than twenty-four hours following processing, the skin is shipped in refrigerated containers via Air Mail Special Delivery to hospitals across the country. Fresh skin should be stored in the refrigerator at approximately 4° C. (39° F.) and used within fourteen days after processing, heeding the expiration date stamped on the label. The skin may be applied at refrigerator temperature or warmed to room temperature for five to ten minutes prior to use (Burn Treatment Skin Bank 1973:4, Wood 1972:720).

Attention must be paid to the refrigeration temperature and the length of time the skin is stored. It has been shown through studies

of skin stored at various temperatures that the cooler the environment the longer the tissue will survive, provided that it does not freeze (Lawrence 1972:450). In 1954, Pepper showed that storage of skin at 4° C. permitted maximum survival, while higher temperatures resulted in a more rapid loss of viability. More recently (1971) Bondoc and Burke demonstrated through measurements of skin metabolism that skin stored longer than fourteen days at 4° C. also loses its viability (Lawrence 1972:451).

Frozen skin has the advantage that it may be stored at freezer temperatures (-18° C. or 0° F.) for up to three months (Burn Treatment Skin Bank 1973:5). The Burn Treatment Skin Bank ships this preparation of skin on dry ice via Air Mail Special Delivery. They recommend that before use, the skin should be thawed quickly in sterile water or saline. This solution may be at or above room temperature, but not above 37° C. Aseptically unrolling the pigskin for greater exposure will decrease the thawing time required. Once thawed, the skin must never be refrozen, but rather stored at refrigerator temperature (4° C.) for up to seven days (Burn Treatment Skin Bank 1973:5).

The freezing of tissues provides a means of storage for extended periods of time but is not without problems inherent in the procedure. Hyatt explained that freezing of tissues should result in immobility without derangement of normal molecular activity. Ideally, the metabolic activity of the graft could be arrested temporarily

for storage, and spontaneously resume upon thawing of the tissue (1959:261). Hyatt continued with an explanation of what physically happens to tissues when they are frozen.

At about 0° C. tissue water begins to form ice. In grafts stored at 0° C. and somewhat lower temperatures, ice crystals increase in size as the storage time lengthens. Theoretically, nothing will remain of the liquid phase of the tissue electrolytes but hypertonic salt solutions after a time. At the late phase of frozen storage, formation of hypertonic salt solutions results in a tissue brine which is lethal to cells and is potentially progressively destructive to the matrix. There must be a point below which tissue electrolytes could be frozen and the graft stored with little significant change from adverse tissue electrolyte concentrations (Hyatt 1959:262).

This microcrystal formation has been noticed by many authors and considered the cause of tissue death "... either because of the mechanical damage, or because of the concentration of salts which appears in the cells and the medium owing to the withdrawal of water into ice crystals" (Santoni-Rugiu 1962:586). Hyatt has raised the following problems for consideration:

1. The significance of ice recrystallization in the state of tissues.
2. The importance of determining the significance of extracellular versus intracellular ice crystals in relation to cell viability.
3. The very real importance of tissue electrolyte concentration as it relates to the irreversibility of cell injury.



4. The significance of the ability of glycerol and other agents to permit so-called "protected freezing" by lowering freezing velocity and reducing tissue-electrolyte concentration in contact with living cells.
5. The high sensitivity of the stable and unstable lipo-protein cell complexes to various freezing velocities, and subsequent frozen storage and thawing.
6. The existence and significance of thermal and mechanical shock to cell and matrix alike as a result of freezing.
7. The existence of tissue enzymatic equilibrium and its importance to cell viability and matrix integrity during freezing, storage, and thawing.

In his article on "Storage and Skin Metabolism" published in 1972, Lawrence suggested that skin could be stored for long periods by treatment with a suitable cryoprotective agent (usually glycerol) followed by controlled freezing to very low temperatures. In the 1950's solid carbon dioxide was the method of choice for long-term freezing of tissues. However, most long-term skin storage systems now use liquid nitrogen (Bondoc and Burke 1971, Lawrence 1972:451). Pruitt and Silverstein have observed that "frozen, viable skin processed with a variety of cryoprotective agents is extremely expensive and must be stored under stringently regulated conditions" (1971:1538).

As stated by Graham in reference to storage of frozen skin, "due to the unpredictability of the occurrence of severe trauma, it behooves a hospital accustomed to treating patients with such injuries to have available large amounts of skin for wound coverage" (Graham 1971:501). A third preparation of skin, lyophilized or freeze-dried, may also meet a hospital's need for skin with long-term storage properties.

Lyophilized skin is harvested with a dermatome, 0.010 to 0.015 inches thick. The skin is then cleansed, soaked in an iodophor solution, rinsed, irradiated and sent through the lyophilization procedure. The rolls of skin are then vacuum packed under sterile conditions and ready for distribution. Following shipping via Air Mail Special Delivery, the pigskin may be stored on a shelf for up to eighteen months without refrigeration. It should be reconstituted in sterile water or a balanced electrolyte solution for fifteen to twenty minutes prior to use.

An attempt to establish quality control standards for the preservation of tissues through lyophilization was made by the Tissue Chemistry Division of the Tissue Bank Department, United States Naval Medical School. Residual moisture determinations following freeze-drying have been found to be a critical index of the skin's keeping qualities. In their laboratory, moisture levels of two to five percent have been accepted as satisfactory.

Lengthening their freeze-drying process does not lower their final moisture content. However, other institutions have other standards. Hyatt observed that it is possible that the varying moisture levels reflect a difference in methods and interpretation rather than actual water content. It was also noted that there was a rapid decline in rate and completeness of solubility if moisture content was in the higher ranges. In addition, Hyatt pointed out that "it is extremely difficult to know whether residual moisture determinations represent the 'free' or the 'bound' water which has been removed along with significant protein alteration and a subsequent notable loss in bio-dynamic capacities of the homograft" (Hyatt 1959:268).

Vacuum-packing is another important part of the storage of lyophilized tissue. "Storage under vacuum minimizes availability of atmospheric oxygen and moisture so that not only is oxidative degradation of fats minimized, but there is very little water substrate available for enzyme activity and decomposition" (Hyatt 1959:268).

The disadvantages of freeze-drying tissues are primarily in the initial expense of the freeze-drying equipment and in the time element involved in processing the grafts before storage. In addition, drying human tissues from the frozen form may be destructive to some enzyme systems (Hyatt 1959:269). Sewell has pointed out that in some types of tissues the freeze-drying process results in less host tissue reaction than is seen with comparable fresh grafts.

"The cells are dead and the process is useful only when mechanical function and not metabolic activity is required of the grafted tissue" (Sewell 1956:360).

The practical advantages of freeze-drying skin for banking, as outlined by Hyatt include (Hyatt 1959:269):

1. The final dried product may be stored at room temperatures.
2. Compared with the original product there is no loss in form or shape of the final dried graft.
3. The method is, theoretically, the least destructive that can be applied to tissue homografts and still achieve long-term shelf storage and centralization of tissue procurement.

Finally, frozen irradiated heterograft is essentially frozen pigskin which has been protected from bacterial contamination by irradiation. It is shipped, stored, sized and thawed in the same manner as fresh porcine skin. It may be stored indefinitely at  $-78^{\circ}$  C. or for six months at  $-18^{\circ}$  C. ( $0^{\circ}$  F.). Its disadvantages lie in the cost of production and its requirement of freezer storage (Burn Treatment Skin Bank 1973:5, Silverstein 1972:ii).

#### Viability

The viability of each of these types of skin has been a topic of considerable debate and research. Questions have been raised as

to how the processing procedure affects the skin, how long-term storage in a particular form affects the skin, and even whether or not the viability of the skin is essential to its effective use.

A series of histologic photomicrographs of fresh pigskin lead Bertke to write the following conclusion: "Throughout the processing procedure the skin remains, to a considerable extent, viable. Preliminary results of oxygen uptake studies corroborate this conclusion" (Bertke 1972:7). Concerning the viability of fresh skin, Moncrief has made the observations that oxygen consumption is normal in autografts up to about twelve hours, after which there is a gradual decrease in oxygen consumption so that by five days it is fifty percent of normal. With homograft, Moncrief continued, "the decrement is somewhat greater, possibly because the cadaver skin loses some of its viability before it is obtained" (Moncrief 1973:450).

The length of time that fresh skin remains viable is estimated differently by many authors, perhaps due to the manner in which the skin was processed and stored, or the method by which the determination of viability was made. About 1950, Flatt and Pepper both reported that fresh skin, commonly wrapped in saline gauze and stored at 4° C., remained viable three to four weeks (Lawrence 1972:440). In 1971 Bondoc and Burke expressed doubt about the clinical usefulness of skin stored over two weeks (Lawrence 1972:440).

Lawrence's experiments on the metabolism of fresh guinea pig skin utilized three measurements to determine viability. His fresh skin was stored in a standard culture medium of homologous serum, Krebs-Ringer phosphate 5 percent w/v glucose and dihydrostreptomycin. Skin respiration was measured with Cruickshank's differential micro-respirometer. The ability of the skin to incorporate sulfate ions and to reduce tetrazolium salts to an insoluble formazan was also studied (Lawrence 1972:440-441). The results of this study indicated that the respiratory activity and the ability of skin to incorporate  $\text{SO}_4$  decreased with storage time.

After fourteen days storage, skin respiration was reduced by fifty percent; sulfate incorporation showed a greater reduction, showing only thirty percent of the initial activity. Measurements made after twenty-eight days storage indicated that the activity of the skin had decreased by 92 percent and 97.5 percent respectively (Lawrence 1972:442).

Tests of the tetrazolium salt reductase capacity of the skin was measured for periods up to seven days. The activity of this enzyme decreased more rapidly than either respiration or  $\text{SO}_4$  uptake (Lawrence 1972:443).

The significance of viability for successful heterograft use is also a question of discussion. In Hyatt's studies with fresh split-thickness human skin stored in a nutrient media (consisting of thirty percent homologous serum, twenty percent chick embryo extract, and fifty percent Earle's saline), Hyatt found that "survival of tissue-culture skin explants was an exacting method, for there

was in vivo survival eight days after skin explants failed to proliferate in tissue culture" (Hyatt 1959:260). Billingham and Medawar have also observed that skin may be viable enough to take as a graft but not grow in the unfavorable environment of a culture (Santoni-Rugiu 1962:587). Concerning the question of whether or not fresh skin is alive or dead, O'Neill has observed

The available information we have about this is that skin obtained in a fresh form is 'alive' for about seven days or thereabouts. Most of these studies have been done with vital staining to demonstrate succinic dehydrogenase activity. Skin one to three weeks old has worked quite well on a temporary basis in our hands, suggesting that the skin does not necessarily need to be completely 'alive' in order to be efficacious (1969:268).

In 1912, Carrel demonstrated homograft viability following storage at temperatures of  $-1^{\circ}$  C. to  $+7^{\circ}$  C. in Ringer's solution or petroleum for up to two weeks. "Thirty-five years later, authors reported success in prolonged homograft storage when anticrystaloids, such as fifteen percent glycerol in Ringer's solution, were allowed to penetrate the cells, and then rapid freezing to temperatures below  $-79^{\circ}$  C. was accomplished" (Pruitt and Curreri 1971:410).

Skoog's studies on the viability of skin stored at various temperatures indicated that "full-thickness skin stored at  $-70^{\circ}$  C. and then thawed was almost indistinguishable from a fresh specimen.

It showed no statistically significant decrease in rate of  $O_2$  consumption or in healing capacity when stored from one to twenty weeks. The respiration rate remained the same as in skin stored less than twelve

hours at +3° C. The freezing process itself, however, did cause a slight but statistically significant decrease in respiration" (Skoog 1954:415). In addition, Skoog found that the quality of human split-thickness skin grafts stored at -70°C. for four to thirteen months was "quite as good as that of fresh homografts" (1954: 416). Georgiade has demonstrated viability of canine heterograft preserved four years in twenty percent glycerol at -45° C. (Pruitt and Curreri 1971:410). Georgiade also made the distinction that quickly thawed skin gave a higher initial  $\dot{Q}O_2$  (mm.<sup>3</sup> O<sub>2</sub> consumption per mg. of dry weight of tissue per hour) than slowly thawed skin preserved under identical conditions (Georgiade 1956:274).

Santoni-Rugiu of Sweden conducted a series of determinations of the oxygen consumption of fourteen day old rat grafts stored in different forms. At grafting time the O<sub>2</sub> uptake was measured by cutting from each graft a small piece of skin weighing approximately one hundred milligrams (according to the method outlined earlier by Skoog). Contaminated samples were discarded. "The determination, carried out with the direct method of Warburg and Bancroft gave the following average values" (Santoni-Rugiu 1962:588):

Control fresh grafts - 0.488  $\mu$ l. O<sub>2</sub> per mg. dry weight  
per hour ( $\pm$  0.019)

Stored deep frozen grafts - 0.174  $\mu$ l. O<sub>2</sub> per mg. dry weight  
per hour ( $\pm$  0.011)



Stored freeze-dried grafts - 0.079  $\mu$ l. per mg. dry weight  
per hour ( $\pm$  0.009)

Santoni-Rugiu interpreted this data, stating that

Judging by these values deep-frozen grafts retained sufficient viability to take if grafted. It was to be expected that the freeze-dried grafts should fail to take since their O<sub>2</sub> consumption was below the minimum found by Skoog, needed for this kind of graft in rats to be viable enough to take (Santoni-Rugiu 1962:588).

There is no debate about the viability of lyophilized skin.

"Dogo and Pate advocated the use of freeze-dried skin grafts as non-vital homografts, able to preserve some of the functions of skin and act as a biologic dressing in selected wounds" (Santoni-Rugiu 1962:587). Moncrief has stated that lyophilization results in dead skin that loses some of the mysterious protective powers of viable skin (1973:450). Santoni-Rugiu's own studies lead him to write that "rat full-thickness skin is not viable when freeze-dried, even if the dehydration is only eighteen percent of the original water content" (1962:589).

Just as lyophilized skin is non-viable, irradiated skin is also known to be dead. For this reason, irradiated skin is often used in studies comparing dead skin with live skin. Burleson and Eiseman's studies on the antibacterial properties of fresh and irradiated skin indicated to them that "confirming both clinical and other experimental data, skin viability is not essential for the antibacterial effect of a biologic dressing" (1973:184).

### Affect of Pigskin on the Wound

The clinical use of each of these types of skin has provided some information as to how the wound and skin affect each other. Studies by Burleson and Eiseman on the in vitro antibacteriologic properties of commercially processed pigskin and their own fresh pigskin had interesting implications. The only difference between the two types of skin was that the commercially prepared skin had received antibiotic and iodophor treatments. The commercially processed skin interfered with bacterial growth; their fresh skin was not able to inhibit staph. These results lead the authors to write: "It was concluded that in vitro bacterial inhibition by commercial pigskin was due to retention of these substances - not to an inherent quality of the skin itself" (Burleson and Eiseman 1973:184).

Considering how long skin will adhere to the wound, Bromberg has written of fresh pigskin that as with any type of temporary covering agent, the degree of adherence and the length of retention are dependent on the status of the wound before application (1965:1607). His studies showed fresh pigskin, sterilized with beta/propiolactone to be effective approximately ten days (1965:1605).

### Immune Response

Abbott's research comparing fresh and preserved skin, noted several immunologic differences between the reaction of fresh homograft and lyophilized homograft on rat wounds. He has concluded that

whereas rejection of fresh homograft was independent of wound size, rejection of freeze-dried grafts is more rapid in animals with smaller wounds than in animals with larger wounds (1970:784). In addition, he has found that using multiple applications of fresh grafts on the mice caused the mice to reject the second fresh graft in accelerated time. However, using the freeze-dried grafts a significant difference was seen. Following one application of freeze-dried grafts, a second set of fresh grafts were rejected in the same rejection time as the first set of grafts (1970:785). Another of Abbott's experiments using hypersensitized and non-sensitized mice showed no difference in rejection time of lyophilized grafts (1970:784). In summary, he has stated that

    viable skin is rejected on an immunologic basis, whereas freeze-dried skin graft survival is a function of wound healing rate. In addition, freeze-dried skin graft survival is a function of wound healing rate. In addition, freeze-dried skin seems exempt from immunologic reactivity. It may be of clinical importance to have a preserved skin graft material which is biologically satisfactory, but which does not sensitize the recipient (Abbott 1970:786).

    Hyatt has also commented that the second-set rejection phenomenon is generally considered an indication of the tissue immunizing capacity of the graft. He observed that freezing, thawing, and freeze-drying are destructive to both DNA and RNA, thereby lessening the capacity of DNA and RNA to elicit a tissue response when the grafts are stored using such methods (1959:253). Sewell stated that freeze-dried

grafts result in less host tissue reaction than is seen with comparable fresh grafts. The cells are dead and the process is useful only when mechanical function and not metabolic activity is required of the grafted tissue (1956:360).

#### Histologic Evaluation

The wound's reaction to graft coverage has also been evaluated histologically. Microscopic observations of dog and rabbit wounds covered with fresh homograft demonstrated slightly deeper fibrosis on the beds of the fresh grafts on dogs.

This reaction in general increased as time of graft survival progressed. In the histologic picture of the beds after sloughing of the grafts there were unevenly distributed masses of polymorphonuclear leukocytes and giant cells, which were especially prominent around fragments of hair (Sewell 1956:360).

Rappaport's dog experiments have shown that there was no significant histologic difference in the granulating bed under fresh and irradiated pigskin. "Apparently, for short-term application the frozen irradiated porcine skin was as effective histologically as fresh refrigerated" (Rappaport 1970:144). According to Silverstein following experimentation with various forms of porcine skin on the rat model, "the histologic appearance of biopsies from wounds xenografted with lyophilized skin resembled those utilizing fresh or frozen porcine grafts" (Silverstein 1972:5).

### Uses of the Various Forms

Clinically, the use of porcine biologic dressings in their various forms is discouraged by some authors and advocated by others.

Stated Silverstein

while fresh porcine skin dressing provide adequate protection to denuded skin surfaces, they suffer from shortcomings of limited viability, possible microbial contamination, and the possibility of eliciting an allergic reaction related to the antibiotic in which they are prepared (Silverstein 1972:1).

On the other hand, he supports the use of lyophilized xenograft.

"It is an adequate substitute for any of the fresh and frozen biologic dressings when used as a temporary wound cover during the period of therapy between the time of eschar separation and autografting" (Silverstein 1972:ii). Experimentation with the use of irradiated pigskin as a temporary dressing lead Silverstein to recognize that subgraft suppuration developed frequently under the xenograft, requiring an average of two or more graft changes. However, when the wounds were free of all debris, the xenograft adhered as well as homograft (1971:2).

An additional clinical difficulty encountered with lyophilized pigskin, is that it will occasionally separate into two layers, leaving debris on the wound which may interfere with autograft take. Unless the skin to be lyophilized is taken at an appropriate thinness, the thicker lyophilized graft is liable to dermal-epidermal separation with desiccation of the exposed dermis and early sloughing (Hackett 1974:429; Pruitt and Curreri 1971:410).

Santoni-Rugiu's studies comparing deep-frozen and freeze-dried autografts showed deep-frozen proved to be much better in respect to take, quick healing and resistance to infection. The difference in healing time is statistically significant" (Santoni-Rugiu 1962:591). He further concluded:

It was interesting to note that homografting of similarly stored skin, final healing occurred sooner with freeze-dried than with deep-frozen skin, both being better than fresh homografts. Judging from their behavior the deep-frozen grafts had a primary take and were then rejected, the marked reaction of the host being responsible for delayed healing. The freeze-dried homografts, acting as a dressing adherent to the wound, allowed epithelization to proceed underneath with consequent quicker healing (Santoni-Rugiu 1962:593).

He explains this behavior on the basis that freeze-dried skin when used as auto-or homografts was not alive to a significant extent, thus reducing host reaction to a minimum when used as homograft. The reduced viability of deep-frozen homografts would account for their superiority to fresh homografts (1962:593)..

### Wound Healing

In order to understand more clearly how grafts affect and interact with wounds the following pages will review literature pertaining to wound healing in general and wound healing beneath grafts. In addition, material concerning the vascularization of grafts and the immune reaction stimulated by the application of biologic dressings will be contained within this section.

### Mechanism of Healing

Immediately following thermal injury, there is edema and exudation of plasma into the injured but viable bordering areas around the wound. Plus, burn edema often occurs in remote uninjured areas of the body, for reasons still not fully understood (Hunt 1971:345). Concurrently, following full-thickness injury is a total occlusion of the vascular supply to the burned area (Moncrief 1973:446). This loss of vascularity results in a gradual deepening of the burn wound, with maximum vascular damage occurring between forty-eight and seventy-two hours following injury (Hunt 1971:345). On the other hand, in a partial-thickness burn circulation to the burn area ceases immediately but is rapidly restored within twenty-four to forty-eight hours (Moncrief 1973:446).

According to Hunt:

After the vascular injury has reached its maximum extent, demarcation between living and dead tissue begins. In superficial second degree burns, epithelial elements alone undergo necrosis, and only separation of superficial epithelium need occur. In deeper burns, damaged capillaries begin to 'heal' and regain their normal permeability; burn edema is thereby reabsorbed (Hunt 1971:346).

This complete reestablishment of circulation in granulation tissue or full-thickness burns occurs approximately three weeks following injury, and is in particular abundance at the interface between burned and unburned tissue (Moncrief 1973:446). With the restoration of circulation more white cells appear, particularly macrophages. At this time the first fibroblasts are also seen (Hunt 1971:346).

The healing process takes place through four stages, as described by Hunt. These steps include: 1) separation of dead tissue, 2) regeneration of connective tissues and vasculature, 3) epithelialization, and 4) contraction (1971:346).

Burn eschar must be removed before epithelialization may occur or before skin grafts will "take." This process may be done surgically (in which the dead tissue is mechanically removed) or progress naturally. When the eschar is left intact, a collagenolytic enzyme appears in the extracellular space of the inflamed area and breaks the collagen bonds. The source of this enzyme is questioned, but it has been suggested that white cells may be the origin. In general this collagenolysis procedure occurs very slowly, and is most effective in small burns where both granulation and epithelialization elements are present. A third process which hastens the separation of dead tissue is infection. Like white cells, many bacteria produce a collagenase which enhances the lysis of eschar. Unfortunately "infection also destroys epidermal vestiges and, in effect, deepens the burn" (Hunt 1971:347).

As the burn eschar is removed, the wound undergoes a regeneration of connective tissue and vasculature. Blood vessels develop, collagen forms, and large numbers of fibroblasts and macrophages appear. Cells at the level of healthy tissue lay down a collagen bed, through which the young blood vessels extend and form a rich vascular network. Into this area migrate macrophages and fibroblasts and the cycle repeats to further advance new tissue.



At this same time, a potential problem begins to develop. With the deterioration of old blood vessels, a dense layer of fibers is synthesized by the fibroblasts present. As the fibrous layer advances and thickens it also begins to contract. This scar tissue may eventually advance to an extent where it limits joint movement and becomes deforming. Interruption of this process by debriding the burn and grafting as soon as the granulation tissue is fully vascularized, minimizes scars and contractures. With skin coverage, the rich vascular supply to the granulation tissue decreases, fibroblasts disappear, and much of the granulation collagen is lysed. In the late stages of healing the collagen is repeatedly deposited and lysed as the wound tissue is exercised and remodeled (Hunt 1971: 348,350).

In second degree burns, epithelial elements survive deep in hair follicles, sweat glands, and apocrine glands. With the removal of dead tissue and the restoration of good vascular supply, mounds of epithelial cells appear at the vestiges of skin appendages and spread rapidly (Hunt 1971:351). If the damage is minimal, the skin buds will grow out in close proximity and healing will occur rapidly with little scarring. The more severe the injury, the fewer epithelial elements survive; and though healing could occur spontaneously in a deep second-degree burn, progress will be slow and the quality of skin will be poor. A third-degree burn by

definition, never exhibits islets of epithelial cells because all epithelial appendages are destroyed. These injuries, if small enough, may heal spontaneously through the migration of epithelial cells from the edges of the wound over the defect. "Each source of epithelium can be trusted to migrate in good quality only a limited distance, usually about ten millimeters. Beyond this extent, epithelialization produces thin layers of poor quality epidermis, under which contracture is likely to occur" (Hunt 1971:350). Thin, poor quality skin remains thin forever, making grafting of deep second-degree burns and large third degree burns desirable and necessary (Hunt 1971:351).

Contraction is the shrinking of a wound following healing due to a migration of normal tissue into the area of previously injured or healing tissue. The process is poorly understood. Hunt wrote, "The skin edges are drawn or pushed together by a mysterious force that probably exists in the cells directly beneath the edge of the wound. The force is independent of both the granulation tissue and the collagen content of the wound" (Hunt 1971:351).

#### The Effect of Grafts on Wound Healing

Following the application of frequently changed homograft to stasis ulcers, Morris, Bondoc, and Burke observed that "the graft has a direct organizational effect on wound healing" (1966:17). It is known that autograft which "takes" prevents further contraction

of an open wound. In addition, richly vascular granulation tissue becomes mature fibrous tissue after the application of split-thickness autograft or homograft (Morris, Bondoc, and Burke 1966:18).

Miller, Switzer, Foley, and Moncrief studied the effects of homograft on second-degree burns on a histologic level. Uncovered burns, they observed, were characterized by a neutrophil infiltrated dermis covered with a crust of fibrin, neutrophils, and cellular debris. Conversely, the dermal inflammation and crust were absent from homograft covered burns of equal depth. Two to three weeks following homograft separation biopsies again revealed startling differences between second degree burns which healed covered and uncovered.

The epidermis of the healed, uncovered burn was dysplastic with areas of atrophy alternating with hyperplasia. There was a disordered maturation sequence of epidermis, from basal cells upward. The epidermis consisted of edematous, immature, vascular connective tissue evolving from granulation tissue (1967:122).

In contrast, the healed homograft-covered burns exhibited a uniform, mature epidermis with an "orderly progressive maturation of epidermal cells." The dermis contained normally arranged, mature collagen fibers with organized papillary and reticular structures (1967:122). The physicians further suggested that the epidermal dysplasia of the uncovered areas may be caused by frequent external stimulation due to trauma and infection. In addition, trauma following healing tended to cause blebs more readily in the burns which healed uncovered

(1967:124). Yen-Ching Lee has noted that hypertrophic scars have developed and persisted in ungrafted areas, while grafted areas reveal what he termed a superior surface after one to three years without hypertrophic scarring or keloid formation (Lee 1972).

Studies of the effect of porcine skin in minimizing necrosis have been carried out by Zawacki with interesting results. Scald burns on the backs of guinea pigs were in some cases left exposed, in others covered with split-thickness pigskin. In both populations capillary stasis progressed to full-thickness depth by sixteen hours postburn. By the second postburn day, in the porcine covered wounds circulation was restored in previously occluded capillaries surrounding the deepest hair follicles. By the fourth postburn day capillary circulation was restored almost to the dermal surface, and by the seventh postburn day it was fully intact. On the other hand, in exposed burns "while some reversal of capillary stasis did occur, it never extended more superficially than it had by the second postburn day, and never to the deepest hair follicles, let alone to the original dermal surface" (Zawacki 1974:100).

#### Vascularization of Grafts

The relationship between the wound surface and the graft has also been researched in terms of vascularization of the grafts. Nathan and Bromberg found that there was apparently no vascularization of pigskin by the third post-graft day (Nathan 1973, Bromberg 1965).

Lee believes that pigskin can live ten days or more on the wound, nourished by a diffusion exchange with the host's dermis. The superficial zone of injury and destruction blocks vascularization, and thus protects the pigskin from the circulation-dependent rejection phenomena of homografts. The skin will fall off of its own accord between the seventh and twenty-sixth day (Lee 1972).

In 1956, Converse and Rapaport published an article entitled "The Vascularization of Skin Autografts and Homografts." Their research done on human subjects, evaluated grafts grossly and by stereomicroscope in terms of intensity of erythema and edema surrounding the graft, graft color, graft consistency, blood flow in graft vessels, and capillary thrombosis. Their findings showed that their skin grafts were without blood at the time of transplantation. Early filling of the vessels occurs by the process of inosculation of host and graft vasculature within twenty-four to thirty-six hours. Ingrowing host vessels are responsible for circulation within the skin grafts. This process of graft vascularization proceeds most successfully when all bleeding in the graft bed has ceased and all subcutaneous fat is removed from the graft prior to its application (1956:311, 312). Concerning homograft, the authors wrote:

Human skin homografts become vascularized. The gross and stereomicroscopic appearance of autografts and homografts is identical in the early stages. The similarity persists until the rejection of the homografts is observed (Converse and Rapaport 1956:314).

Studying vascularization of homografts on mice by the injection of Evans blue dye, Bromberg and Song observed that "the grafts became well vascularized during the first few days, but were rapidly invaded with inflammatory cells. Dehydration and necrosis were evident by seven days" (1965:83). Pigskin grafts were also examined, revealing a normal histologic picture and staining properties for several weeks. However, several days post-grafting, dehydration and necrosis could be visualized at the edges of the graft, and cytoplasmic basophilia was lost from the epidermis. "All of the grafts remained nonvascular and were rarely invaded by host cells. Wound healing progressed slowly and minimal phagocytic activity was observed" (Bromberg and Song 1965:83).

Larson has noted that in porcine skin applied to rats, no circulation was ever seen in the split-thickness heterografts viewed under dissecting microscopes.

The injection of carbon particles prior to sacrificing the animal revealed that xenograft vessels, in contrast to homografts, do not contain carbon particles. This indicates that the graft is not vascularized by the recipient host; however, neutrophils did infiltrate the graft from capillaries in the underlying granulation tissue, demonstrating that cellular interaction is possible (Larson 1973:180).

The frequent erroneous reference to the "take" of porcine skin, lead Pandya to further investigation of the mechanisms by which pigskin heterografts adhere to wounds. He noticed that on the second day postgrafting, the vessels in the mouse recipient bed became slightly dilated and some edema was evident in surrounding

areas. During the fifteen days of observation, the dilatation of the vessels in the vicinity of the graft persisted with subsidence of the edema by the ninth day (1974:212). The adherence of the heterografts to the wound and the appearance of a pink hue through the graft have on occasion, been considered evidence of graft "take." Pandya's study supported the statement by Pruitt and Curreri that canine heterograft tends to be inert on the burn surface (Pruitt and Curreri 1971:414). Pandya explained that the adherence and coloring "are likely the effects of a fibrinous adherence between the grafts and the underlying wounds (plus the hyperemia in the underlying wound observed through the thin transparent graft)" (1974:213). Of the ninety-six porcine heterografts, vascularization occurred in none and no difference could be seen in the wound's response to the various preparations of porcine grafts (Pandya 1974:212).

#### Immune Response Stimulated by Pigskin

The immune response of humans to porcine xenografts has not been studied extensively. The immunologic nature of homograft rejection is more clear. Smith has reported the sequence of events in homograft rejection both grossly and microscopically. Grossly, he has observed that by the tenth to twelfth day the graft becomes necrotic, the vascular supply is lost, and rejection is complete. Following the placement of a second-set graft, the reaction progresses

more rapidly. "Vascularization usually never proceeds beyond the first ingrowth of capillaries. By the tenth day nothing but an eschar remains" (Smith 1972:16). Microscopically, lymphocytes begin to accumulate around the graft vessels by the sixth to eighth day, followed rapidly by an infiltration of macrophages. The vessels then become occluded in areas, and with the death of the graft is the appearance of polymorphonuclear leukocytes. In second-set rejection, polymorphonuclear leukocytes play a major role, though again lymphocytes and mononuclear elements are involved (Smith 1972:16).

The antigens recognized as initiating allograft rejection are the proteins or glycoproteins which are integral structural elements of the cell surface membrane. Cell membrane antigens are the only known transplantation antigens by which graft rejection is mediated (Smith 1972:17). However, it is still unknown whether graft rejection is antibody mediated, cell mediated, or caused by a unique non-immune mechanisms (as a cytotoxic effect of one cell upon another when their cell surfaces differ in any way). Possibly all three mechanisms are involved. The antibody reaction is complex, with its effects including chemotaxis, release of anaphylatoxin which has effects on vascular permeability, and aggregation of cells (Smith 1972:18). In the cell mediated response, the lymphocyte plays the primary role by setting off a series of destructive reactions



when it comes in contact with a foreign cell surface (Smith 1972:17). In addition, with an inflammatory response caused by recognition (either cell or antibody mediated) are vascular effects including platelet stickiness, sluggish capillary flow, leukocyte platelet thrombi, and vasoconstrictive or vasodilator effects, which all contribute to graft disposal (Smith 1972:18). The patient responds with an overall reaction of fever, irritability and anorexia (Shuck 1969:473).

At an Orthopedic Conference in 1972, Mast reported that although antidog antibodies have been found in patients treated with repeated dog heterografts, there is no mention in the literature of similar antibodies against pigskin. Similarly, there have been no reports of significant hypersensitivity reactions in patients treated with pigskin, although we had two patients in which pigskin was discontinued because they developed erythema, edema, and puritis in the tissues directly in contact with the porcine grafts (1972:7).

Various authors have suggested that xenograft does not cause an immune reaction, based on several observations: 1) The xenograft is not vascularized; 2) subcellular porcine skin extracts injected intradermally into human patients before and after porcine xenografting do not elicit delayed hypersensitivity; and 3) porcine skin extract, injected intravenously into rabbits, fails to produce precipitin antibodies against the extract (Harris and Abston 1974:599).

Harris and Abston undertook a study "to illustrate that by suitable assay procedures, the act of xenografting with porcine skin in burned patients elicits an immune reaction" (1974:599). Following eschar separation (about twenty-five days postburn) fresh

pigskin was placed on the wounds. The twenty-seven patients were bathed daily and non-adherent pigskin was replaced with fresh xenografts. Assay of antiporcine antibodies was done through a variation of the Terasaki leukocytotoxic assay. Their results indicated that the titer against pig lymphocytes rises in a step-wise manner, reaching a peak after four applications of pigskin. Subsequent grafting did not increase the level of sensitization. Before grafting, a background titer of about 1:20 was found in most patients. Patients receiving xenografts developed a mean titer of 1:565 which remained for approximately sixty days, followed by a mean titer of 1:154 by ninety days. No relationship of antiporcine antibody response was found to age, sex, blood type, or percent burn; the only variable affecting the response being the number of pigskin applications (Harris and Abston 1974:600).

The results of this study lead the authors to believe that vascularization is not necessary for xenograft sensitization (Harris and Abston 1974:600). In addition, whereas the injection of porcine extracts fails to elicit an immune response (indicating that this is not a cellular immune response), the authors feel that xenograft reaction seen in this study is an antibody mediated reaction (1974:601). Harris and Abston conclude, "In this present study, it was demonstrated that cytotoxic antibodies against viable pig lymphocytes were definitely produced in every xenografted patient who was studied" (1974:602). This study should also be viewed in light of the fact that burned

patients are immunologically depressed and that the clinical significance of this research is unknown, in that regard (1974:602).

A similar study, conducted by Law, Nathan, and MacMillan had much the same results. Again the patient sensitization to porcine xenografts was evaluated using Teresaki's lymphocyte cytotoxicity technique. Their results indicated that with temporary application of xenograft, a transient increase in titer with subsequent fall to normal occurred (1969:3). When a second application of xenograft is used, redevelopment of antibody titer occurs promptly and higher levels may be reached. Following the removal of xenografts, a prompt rise in antibody titer occurs, usually followed shortly by a return to normal levels (1969:4). Again, the response did not appear to correlate with the size of the burn or with the severity of the illness (1969:3).

McCabe performed a study from which he drew slightly different conclusions. Employing a skin-window technique, coverslips were changed at three, six, twelve, twenty-four, and forty-eight hours and the adhering leukocytes analyzed. Quantitative analysis determined the general level of host resistance, and qualitative determinations of the proportion of immune-neutral monocytes to the immune-competent lymphocytes indicated the degree of sensitization to the test antigen (1973:182). Their results revealed an initial non-immune response

of burned patients to multiple applications of pigskin, followed by an increasingly immune-competent cellular reaction which peaks at thirty days. No clinical manifestation of the sensitization was seen (McCabe et al. 1973:187).

From the information just presented, the manner in which wound healing progresses may be seen. When grafts are placed upon the wound, wound healing is improved. Also, whereas homografts are vascularized and known to elicit an immune reaction, porcine xenografts are not vascularized and the immune response evoked is not at all well understood. The final section of this chapter will deal with the nurse's role in caring for burned patients with homografts or heterografts.

### Wound Management

In this section of the review of literature, some of the goals in wound management and basic concepts of treatment will be presented. In addition, the nurse's role in the observations, decisions, and procedure of heterografting will be covered. Finally, the technique for heterografting will be included.

### Objectives of Wound Care

Following the emergency phase of patient care required by the burn victim, is a wound management phase lasting until all wounds are healed or grafted (Jacoby 1976:5). The importance of good nursing care and burn wound management during this phase cannot be

over emphasized. Improper wound care leads to severe contamination, including wound infection, systemic sepsis, and conversion of partial-thickness burns to full-thickness injuries. These complications may necessitate more grafting, increase scarring and contractures, and prolong hospitalization (Feller 1973:115). The burn team's goals during this phase include such aims as those suggested by Jacoby (1976:5):

1. Wound cleansing
2. Preparing wounds for grafting
3. Preventing and minimizing infection
4. Closing burn wounds and preserving body functioning
5. Meeting nutritional and psychological needs of the patient

Khalili noted that to prevent unfavorable burn complications, preventative measures should be started from the first day of hospitalization and continue until recovery goals have been reached. "These measures require a meticulous, continuous, and collaborative professional effort" (1969:43). Jacoby (1976:37-38) has written three basic concepts playing a key role in the treatment of burn wounds. These include:

1. Keeping the patient's general condition as stable as possible by meeting his physical and emotional needs
2. Keeping infection to a minimum

3. Pursuing an aggressive course of definitive care with close attention to the details of each particular treatment.

To these objectives for wound care, Feller adds the following (1973:115):

1. To prevent conversion of a partial thickness burn to a full-thickness wound
2. To remove all dead tissue
3. To prepare healthy granulation tissue for grafting
4. To complete autografting as soon as possible, using biologic dressings for temporary cover when necessary
5. To minimize the scars and contractures.

Because the nurse spends more time than any other member of the health team with the burned patient, he must be attuned to the occurrence of physiological and psychological problems. Khalili stressed "supportive nursing personnel who spend considerable time with individual patients should fully understand and appreciate the goals and rationale of treatment" (1969:43). The nurse has a considerable influence on the patient's adjustment to pain, disfigurement, long term care, and discouragement which are all a part of nearly every burn victim's course (Feller 1973:71, Khalili 1969:43). An attitude of genuine interest and concern, in addition to strong emotional support are very important to the welfare of the burned

patient. The burn nurse's job includes alleviating the patient's anxieties by orienting him to his surroundings, and preparing him for what he can expect from equipment and procedures. The nurse must also make pertinent observations on the physical and emotional status of the patient, and carry out his assignments in such a manner as meets the patient's needs maximally (Feller 1973:71).

#### Heterografting Procedure

Before beginning the dressing change or heterografting procedure, the nurse should consider three factors contributing to good patient-care. Infection control should always be a portion of the nurse's thought processes (Feller 1973:117). Brunner has suggested that to keep cross-infection to a minimum, personnel should all wear masks, gowns, and gloves during dressing changes (Brunner 1970:670, Jacoby 1976:72). Keeping certain burned areas covered with sterile dressings or sterile sheets if indicated, minimizes infection; and using rigid aseptic technique during dressing changes is also necessary to protect the patient from infection (Brunner 1970:670).

In addition to infection control, the nurse must bear in mind the importance of providing pain relief and emotional support prior to dressing changes. And finally, the nurse needs to minimize chilling throughout the procedure. This may be done by keeping the dressing changes as brief as possible, covering areas which are not being treated, employing a heat shield, and performing the procedure in an area free of drafts (Archambeault 1973:117-118).

Though occasionally biologic dressings are applied in the operating room following debridement (Shuck 1969:473), the majority of heterografting is done on the ward by nursing personnel (Baxter 1970:3).

Before beginning the dressing change, equipment needed should be assembled (sterile gloves, forceps and scissors, a basin or other sterile field, pigskin, antibiotic gauze, and dressings to be applied). If lyophilized pigskin is being used, reconstitution in sterile, room temperature, physiologic saline should be done before the patient's wounds are exposed (Silverstein 1972:3). Once the dirty dressings are removed, the grafting and reapplication of dressings should progress as efficiently as possible. At this time, the patient's weight should be taken and recorded, if indicated. The patient should be weighed daily (without dressings) during his acute phase of recovery (Feller 1973:70).

Jacoby has listed the steps of the heterografting procedure (1976:162):

1. Explain the procedure to the patient
2. Medicate the patient as ordered by the physician
3. Cleanse the recipient area
4. Open containers holding grafts
5. Cut grafts to the appropriate size
6. Smooth grafts in place and trim edges



7. Cover with a dressing if ordered
8. Record the site grafted and the date
9. Check the grafts daily

In preparing the patient for the procedure, an explanation of what the patient may expect is essential to alleviate anxiety. Whereas the debridement prior to application of heterografts may be painful, the actual application of pigskin usually is not particularly painful and may be done on the ward without anesthesia (Pruitt 1971:400). Minckley has found that the use of television as a distractor during dressing changes can be a valuable tool for a nurse (1970:1893).

After medicating the patient, the dirty dressings are removed and the recipient area is cleansed to make it ready for the graft. With removal of the soiled dressings, signs of infection such as odor, color changes, and cellulitis should be noted by the nurse and reported to the physician (Shafer 1971:727). The wounds are cleansed with a mild agent to remove any slough over the partial-thickness wound (Jacoby 1976:50).

When the wounds are clean, the graft containers are opened, and the pigskin placed on a sterile field. Gloves are changed, and the nurse applies the heterograft. The dermal side of the skin is placed against the wound (Pruitt 1971:400). If it is questionable which side is the dermal side and which is the epidermal side, it should be remembered that the dermal side is usually more glossy,

and that porcine skin has the tendency to curl towards the dermal side (Burn Treatment Skin Bank 1973:6). The graft is smoothed with a blunt surface to remove all air pockets, to ensure close apposition of the graft to irregularities in the wound bed, and to prevent inversion or curling of the graft edges (Pruitt 1971:400). Wrinkles and overlapping of the graft should be avoided (Burn Treatment Skin Bank 1973:6). Adjacent sheets of the biologic dressing should be contiguous to prevent desiccation of exposed granulation tissue and pseudo-eschar formation. Sutures are not needed (Pruitt 1971:401).

#### Care of Grafted Wounds

The heterograft-covered wounds may be left exposed or dressed in moist saline gauze or stretchable tubular net dressings (Silverstein 1972:3). Bromberg has recommended the use of local drug therapy simultaneously with the grafts (Bromberg 1970:1646). Feller and Archambeault have suggested that the application of a sterile fine mesh gauze dressing saturated with saline or the topical agent of choice, may be used to secure the grafts in place (Feller 1973:142). Silverstein has pointed out that circumferential burns which are covered with heterograft, nearly always need to be wrapped with a gauze dressing to prevent dislocation due to shearing against the bed linens (Silverstein 1972:3). Heterografts on the very young, the confused, and the agitated patient usually must be secured with dressings as well (Pruitt 1971:401).

Grafts must be inspected daily, so that non-adherent portions of the graft may be debrided, and subgraft collections of purulent material or serum evacuated (Pruitt 1971:401, Shuck 1969:473, Bromberg 1970:1646). If exudate does accumulate within twenty-four to forty-eight hours, the grafts should be removed, the wounds washed, and new grafts applied (Stone and Boswick 1969:28). Grossly infected wounds may require daily dressing changes at first (Elliot 1973:402). As the wound becomes cleaner, and the pigskin adheres, it may optimally be changed every four or five days to facilitate the debridement of the separating outer dermis; or, in a second degree burn, may be left in place until it is separated by the completely healed dermis underneath (Baxter 1970:4).

Physical therapy and whirlpool tanking may be employed twenty-four to forty-eight hours after heterografting while the dressings are in place (Stinson 1974:112). If the wound is large or very dirty, the patient may be bathed in a Hubbard tank every day or two. Should the heterograft come off during the tanking procedure, a fresh graft may be placed on the wound when the patient comes out of the tank (Luckmann and Sorensen 1974:1288).

Unexplained fever, toxemia from an otherwise unidentifiable source, or excessive subgraft purulence warrant immediate graft removal and assessment of the wound for further mechanical debridement and possible reinstitution of topical chemotherapy before the application of more heterograft (Pruitt 1971:402).

In summary, the management of the patient receiving pigskin heterografts to his burn wound is to a large extent the nurse's responsibility. Though not a difficult procedure to perform, strict attention must be paid to the patient's status before grafting, aseptic technique used during the graft and dressing application, and the condition of the patient and the patient's wounds in the hours following heterografting. The wound management phase of the burn patient's course is a serious and potentially lethal period. At this time attention must be paid to the whole patient in preparing him for hospital discharge. During this phase, grafting techniques are usually used in combination with daily dressing changes, exposure techniques, whirlpool and debridement, nutritional management, physical therapy, pulmonary management, and fluid and protein management in the burn patient's rehabilitation (German 1972).

#### Summary

In this chapter, a review of the historical significance of grafting has been presented in addition to the advancements made in recent years in the use of heterografts as a temporary biologic dressing for open wounds. The advantages, disadvantages, and various uses for porcine heterografts have been reviewed, with a discussion of the differences between porcine heterografts prepared in different ways. A brief explanation of the normal physiology of wound healing and the effect pigskin heterografts have upon the

process was presented. And finally, the responsibilities of the nurse in preparing a patient for heterografting, carrying out the procedure, and monitoring the effect the heterograft has on the patient was discussed.

In the following chapter, the methodology used to carry out this study, will be covered. And in the final two chapters, the data collected will be presented with the results, conclusions, and recommendations which have emerged as a result of this study.

## CHAPTER III

### PROCEDURE FOR COLLECTION AND TREATMENT OF DATA

An experimental study was conducted to evaluate the effects of both fresh and lyophilized pigskin on the healing process of second degree burn wounds in man. The study was carried out in the Dallas Burn Center, with the population being treated on an out-patient basis. The description of the procedure and instrument used for the collection of data the method used to analyze the information will be included in this chapter.

#### Setting

The setting for the collection of data was the physical therapy department in an eight-hundred bed county hospital. Agency permission was obtained to perform this study on individuals being treated for burns on an out-patient basis (Appendix A.). The study was reviewed and approved by the Human Rights Committees of Southwestern Medical School and Texas Woman's University (Appendix B.).

The population treated at the Burn Center were primarily from the North Texas area. Those patients with small or uncomplicated burns are frequently seen as out-patients and evaluated by the physical therapy department every day or two as their condition warrants. At this time physical therapy, hydrotherapy, and topical treatment are instituted. The patients are also seen weekly by the burn physicians in burn clinic.

### Population

The patients eligible for this study were patients with second degree burns covering between two and twenty percent total body surface area and ranging in age from ten to sixty-five. The population was screened with notation of patients with a history of skin disease, vascular disease, or other chronic systemic disease affecting either the skin or vascular systems. Patients were also questioned as to any recent history of illness or drug therapy. Subjects eliminated from the study were patients with burns in areas which could not be biopsied for cosmetic or functional reasons (face, hands, or joints). Written permission to apply the two types of pigskin, and to take cultures and photographs of the wounds was obtained from each patient. In addition, consent was obtained for two wound biopsies from burned areas which healed under fresh and lyophilized pigskin (Appendix C.).

Over a seven month period, nine patients met the above criteria and agreed to take part in the study. These patients ranged in age from thirteen years to twenty-five years, having second degree burns ranging in size from two to fifteen percent total body surface area. Six of the burns were caused by scalding liquids, and four were caused by some type of explosion. Six of the patients had upper extremity burns, two suffered burns of the chest and shoulder. One patient had burns of the abdomen, and one had thigh burns. Six of the patients had at least two burns large enough to be covered with the two types of skin. Both lyophilized and fresh skin were applied to each area.

### The Tool

The permission form designed by the researcher discussed what the study would entail in terms of the use of fresh and lyophilized pigskin, and the taking of cultures, photographs, and two biopsies (Appendix C.). In the permission form, it was also specified that withdrawal of consent to participate in the study would be honored without affecting the individual's status as a patient.

The tool used for collecting the data was developed by the researcher in several segments. An initial evaluation form was established to identify the factors which could influence the healing process (Appendix D.). This patient information sheet contained demographic data including age, anatomical areas burned, date and cause of injury, and percentage of second and third degree injury. In addition, patients were screened for history of heart disease, syphilis, diabetes, renal disease, stasis ulcers, cerebral vascular accident, anemia, emphysema, bronchitis, tuberculosis, cancer, leukemia, hepatitis, and skin disease. Recent illnesses, allergies, and medications being taken were also noted.

After the application of the pigskin, an anatomical chart was used for diagramming the burned areas involved in the study and the placement of the two types of pigskin (Appendix E.). This chart was designed from enlargement of the burn chart used on the burn unit to diagram areas of burn injury.



Finally, a form was developed for collection of data on patient's return visits to physical therapy (Appendix F.). On each visit, the postburn day was calculated and the procedures completed were noted. Entries were made to denote whether or not photographs were taken, and to numerically indicate areas which were cultured or biopsied, and where pigskin was reapplied or trimmed. In addition, the adherence of the pigskin and the amount of inflammation were graded on scales of one to five. On each visit the researcher evaluated and recorded the degree of healing beneath each of the types of skin. Space was also available on the same page to record culture results (grading the level of bacterial contamination of the wound on a scale of one to five) and to attach photographs.

#### Procedure for Collection of Data

On arrival in the emergency room, the wounds were washed with a Betadine solution, debrided and creamed with silver sulfadiazine. The patients were then referred to the physical therapy department. In physical therapy the patient was interviewed to obtain a brief medical history, the protocol was explained, and written permission to be placed on the study was obtained. Silver sulfadiazine topical therapy was continued in some cases until the wounds were ready to be pigged.

Initially, in physical therapy, the wounds received hydro-therapy and were cultured. Photographs were taken prior to the

application of pigskin. Lyophilized pigskin was reconstituted for twenty minutes in room temperature saline before use. The wounds were then covered with alternating three-inch strips of fresh and lyophilized porcine skin. The location of each strip was diagrammed and numbered on anatomical charts of the body for future reference. Alternating strips of heterograft were applied to the entire burn surface using sterile technique, in adjacent but non-overlapping strips. Pigskin extending over the edges of the burn wound was trimmed off. Finally, the wounds were wrapped with Garamycin gauze and secured with Kling gauze wrap. Written instructions were given to each out-patient, requesting him to leave the pigskin in place, to keep the wound dry, and to return to physical therapy as scheduled (Appendix G.).

The patients returned to physical therapy a minimum of three times per week. At each visit the adherence of each strip of pigskin in each area, and the gross inflammation of the area surrounding the burn were evaluated on scales of one to five. The adherence of the pigskin received a rating of one if it was firmly adhered after tanking, a rating of two if it was in place but not "tight" following hydrotherapy, a rating of three if it sloughed off during tanking, a rating of four if it sloughed off partially prior to tanking, and a rating of five if the skin totally sloughed off with the removal of the dressing. In the same way, the level of gross inflammation was assessed. A rating of one indicated that no cellulitis

was present around the burned area. The wound received a rating of two if pink edges extended less than .5 centimeters around the wound, a rating of three if a pink to red area extended .5 centimeters around the burn, a rating of four if a red, painful area extended greater than two centimeters from the burn, and a rating of five if a red and painful area extended more than two centimeters from the wound and color changes within the wound could be identified. These ratings were assigned by the researcher and/or the head of physical therapy on each visit and documented on flow sheets.

On each return visit, after non-agitated tanking, the non-adhering heterograft was trimmed off and the wound again evaluated. Photographs were taken of the wounds initially and a minimum of every fourth day. Rodac plate surface cultures were also taken on each wound initially and when the pigskin failed to stick. Bacterial growth was graded on a scale of one to five as indicated by no growth, light, medium, heavy, and confluent growth on the rodac plates (Appendix H.). When the pigskin sloughed off, the burns were recovered with fresh heterograft placed over areas previously covered with the fresh skin, and lyophilized pigskin over areas previously covered with lyophilized skin.

When the pigskin separated from the burn and healing was complete beneath the two types of pigskin, two skin-punch biopsies were taken from representative areas which healed beneath the fresh

and freeze-dried pigskin. The biopsies were placed in formalin and sent to the pathology department for comparative microscopic evaluation of healing characteristics by Dr. Robert Freeman, Professor of Dermatopathology (Appendix I.).

#### Procedure for Treatment of Data

This study has provided several parameters for comparison of wound response to fresh and lyophilized pigskin. The adherence of the two types of skin, inflammation of areas surrounding the skin, and bacterial growth measurements were each evaluated as associated with each type of heterograft. Healing time was also measured in terms of days, as supported by clinical evaluation and photographs. And finally, the comparative histologic report by the pathologist has shed some information on this wound healing.

With the relatively small sample of patients obtained for this study, the information gathered was evaluated by implementation of the sign test and averages. In addition, identified trends will be presented, that the clinical significance of this study may be determined by the reader.

#### Summary

In this chapter, the methodology employed to gather information concerning the effectiveness of fresh and lyophilized pigskin heterografts on wound healing has been presented. The following chapter will analyze the data collected through the course of this case study. Finally, Chapter V will summarize the implications and recommendations derived from this study.

## CHAPTER IV

### ANALYSIS OF DATA

Fresh and lyophilized skin was placed on nine patients being followed in physical therapy with second-degree burn wounds. In this chapter, the data which was collected concerning the healing of these wounds will be presented. In each case, comparisons were made between the behavior of the wound being treated with fresh pigskin and that being treated with lyophilized pigskin.

A total of thirteen wounds were followed in this study to evaluate and compare the healing processes beneath the two types of pigskin. The wounds were covered with pigskin as heterograft therapy became appropriate treatment. All the wounds received pigskin by the ninth postburn day.

All patients were screened before being placed on the study. No patients had any known diseases affecting the skin or circulatory systems. All patients were well and none were taking medications prior to the injury. The nine patients ranged in age from thirteen to twenty-five years. The causes of the injuries included explosion, fire, scald, and hot grease. The burn sizes ranged from three to fifteen percent total body surface area. Wounds were first heterografted either on the day of injury, or when the wounds were adequately debrided. The longest topical treatment interval was nine days (See Table 1.).

TABLE 1  
DEMOGRAPHIC DATA

| <u>Patient</u> | <u>Age</u> | <u>Type of Burn</u> | <u>TBSA Burned</u> | <u>Post-burn Day First Pigged</u> |
|----------------|------------|---------------------|--------------------|-----------------------------------|
| A              | 24         | Oven explosion      | 5%                 | 1                                 |
| B              | 22         | Gasoline fire       | 4%                 | 3                                 |
| C              | 13         | Scald               | 6%                 | 9                                 |
| D              | 16         | Scald               | 15%                | 0                                 |
| E              | 15         | Gasoline fire       | 5%                 | 5                                 |
| F              | 23         | Grease              | 5%                 | 7                                 |
| G              | 24         | Scald               | 5%                 | 2                                 |
| H              | 22         | Scald               | 3%                 | 4                                 |
| I              | 25         | Scald               | 4%                 | 3                                 |

Bacteria Levels

Bacterial levels were evaluated prior to the first application of pigskin and when the pigskin failed to adhere to the wound. Rodac plate cultures were used. Initial cultures on six wounds prior to pigskin application revealed light colonization. One wound (patient E) exhibited heavy colonization on the initial rodac plate culture (see Appendix H for further explanation of culture results). Surprisingly, both types of pigskin adhered readily to this wound, and the wound healed by the seventh postburn day. Thus subsequent cultures were not taken.

Four wounds required culturing on the patient's first return visit due to failure of the pigskin to adhere to the wound (see Table 2). On three of the wounds, bacterial growth remained the same or decreased following application of the pigskin. On the fourth (wound 4) an increase in bacterial count was seen in the portion of the wound treated

with fresh pigskin, while the bacterial count remained the same beneath the lyophilized pigskin. This finding may have been due to the use of a contaminated roll of fresh pigskin.

By the second return visit, only two patients had non-adhering pigskin (patients C and H). In both cases, bacterial contamination had increased from light growth initially to heavy colonization by the third visit. Wound 3 was not yet healed when the patient stopped coming to physical therapy; wound 12 sloughed a third application of pigskin and subsequently healed following treatment with Silver Sulfadiazine (see Table 2).

TABLE 2  
CULTURES

| PATIENT<br>WOUND     |                    | A<br>1 | B<br>2 | C<br>3 | C<br>4 | D<br>5 | D<br>6 | E<br>7 | E<br>8 | F<br>9 | G<br>10 | G<br>11 | H<br>12 | I<br>13 |
|----------------------|--------------------|--------|--------|--------|--------|--------|--------|--------|--------|--------|---------|---------|---------|---------|
| INITIAL CULTURES     |                    | 2      | 0      | 2      | 2      | 0      | 0      | 4      | 0      | 2      | 0       | 0       | 2       | 0       |
| RETURN<br>VISIT<br>1 | <u>GRAFT</u>       |        |        |        |        |        |        |        |        |        |         |         |         |         |
|                      | <u>FRESH</u>       | 1      | 0      | 2      | 4      | 0      | 0      | 0      | 0      | 0      | 0       | 0       | 2       | 0       |
|                      | <u>LYOPHILIZED</u> | 0      | 0      | 1      | 2      | 0      | 0      | 0      | 0      | 0      | 0       | 0       | 2       | 0       |
| RETURN<br>VISIT<br>2 | <u>FRESH</u>       | 0      | 0      | 0      | 4      | 0      | 0      | 0      | 0      | 0      | 0       | 0       | 4       | 0       |
|                      | <u>LYOPHILIZED</u> | 0      | 0      | 0      | 4      | 0      | 0      | 0      | 0      | 0      | 0       | 0       | 4       | 0       |

Culture Growth Key

- 0 = no culture taken
- 1 = no growth
- 2 = light growth
- 3 = medium growth
- 4 = heavy growth
- 5 = confluent growth

### Adherence

The adherence of the fresh and lyophilized pigskin was evaluated on each return visit to physical therapy. Pigskin which sloughed off with the removal of the dressing was given a "five" classification. This was seen in three wounds following the initial application of pigskin, and in two cases following the second application of pigskin. (See Table 3). A rating of "four" indicated that the pigskin sloughed partially with the removal of the dressing.

Pigskin which adhered to the wound until non-agitated tanking causing it to slough was classified with a "three." The two patients (patients C and H) whose pigskin adherence never improved over a rating of three, both had heavy colonization on the rodac plate cultures. Patients whose pigskin adherence received a rating of three, four, or five had pigskin heterografts reapplied.

An adherence rating of two indicated that following hydrotherapy, the pigskin was still in place, but not tight. When this occurred, the pigskin was left in place. A rating of one was granted when the pigskin was firmly adhered following tanking.

Analysis of adherence ratings revealed some interesting results. On the first return visit, the adherence rating of the fresh pigskin was higher (poorer adherence) than that of the lyophilized in five of the thirteen wounds (See Table 3). On the second return visit, the adherence of the fresh pigskin was superior in two wounds (5 and 6); and the



adherence of the lyophilized was superior in two wounds (1 and 4). Using the sign test to evaluate these results indicated seven positives (seven occasions where superiority of fresh pigskin could be demonstrated) and two negatives (two occasions where superiority of lyophilized could be demonstrated). These findings are not statistically significant.

Looking at the data clinically, one may see that in one patient, patient D, the adherence was significantly better using fresh heterograft as opposed to lyophilized pigskin. In both of his wounds, on two consecutive visits to physical therapy, the fresh pigskin adhered tightly, while the lyophilized sloughed with the removal of the dressing (See Table 3). No outstanding characteristic could be seen about this patient setting him apart from the others. He was a sixteen year old male with approximately fifteen percent total body surface area scald burn, and no significant medical history. After three return visits to physical therapy, he never returned for further evaluation of his wounds.

#### Number of Applications Required

The number of applications needed correlates closely with the adherence, as an adherence rating of three, four, or five requires an additional application of pigskin. On an average, 1.69 applications of fresh pigskin were required on each wound, and 2.07 applications of freeze-dried pigskin were needed.

TABLE 3  
ADHERENCE OF HETEROGRAFTS ON SUBSEQUENT VISITS

| PATIENT<br>WOUND     |             | A | B | C | C | D | D | E | E | F | G  | G  | H  | I  |
|----------------------|-------------|---|---|---|---|---|---|---|---|---|----|----|----|----|
|                      |             | 1 | 2 | 3 | 4 | 5 | 6 | 7 | 8 | 9 | 10 | 11 | 12 | 13 |
| RETURN<br>VISIT<br>1 | GRAFT       |   |   |   |   |   |   |   |   |   |    |    |    |    |
|                      | FRESH       | 3 | 1 | 5 | 5 | 1 | 1 | 1 | 2 | 1 | 4  | 4  | 1  | 1  |
|                      | LYOPHILIZED | 3 | 3 | 5 | 5 | 4 | 5 | 1 | 2 | 1 | 5  | 4  | 3  | 1  |
| RETURN<br>VISIT<br>2 | FRESH       | 3 | 1 | 1 | 5 | 1 | 1 | 1 | 2 | 1 | 2  | 1  | 3  | 2  |
|                      | LYOPHILIZED | 1 | 1 | 1 | 3 | 5 | 5 | 1 | 2 | 1 | 1  | 1  | 3  | 2  |
| RETURN<br>VISIT<br>3 | FRESH       | H | H | 1 | 2 | 1 | 1 | H | H | H | 1  | 1  | 3  | 1  |
|                      | LYOPHILIZED | H | H | 1 | 2 | 1 | 1 | H | H | H | 1  | 1  | 3  | 1  |
| RETURN<br>VISIT<br>4 | FRESH       | H | H | H | 3 | H | H | H | H | H | H  | H  | R  | H  |
|                      | LYOPHILIZED | H | H | H | 3 | H | H | H | H | H | H  | H  | R  | H  |

Adherence of Pigskin Key

1 = firmly adhered following hydrotherapy  
2 = in place, but not "tight" following hydrotherapy  
3 = sloughed off during tanking  
4 = partially sloughed prior to tanking  
5 = totally sloughed off with removal of dressing  
R = removed pigskin  
H = healed

On one wound (wound 1), a single extra application of fresh pigskin was necessary; on two wounds (wounds 2 and 12) one additional application of lyophilized pigskin was necessary. On two wounds, two additional applications of lyophilized pigskin were required. Again, the two wounds which responded most poorly to lyophilized pigskin were on the same patient (patient D). Utilization of the sign test to evaluate the number of necessary applications of each type of skin, reveals four positive values and one negative value, or an insignificant difference between the two (See Table 4).

TABLE 4  
NUMBER OF HETEROGRAFT APPLICATIONS

| PATIENT<br>WOUND | A | B | C | C | D | D | E | E | F | G  | G  | H  | I  |
|------------------|---|---|---|---|---|---|---|---|---|----|----|----|----|
|                  | 1 | 2 | 3 | 4 | 5 | 6 | 7 | 8 | 9 | 10 | 11 | 12 | 13 |
| FRESH            | 3 | 1 | 2 | 3 | 1 | 1 | 1 | 1 | 1 | 2  | 2  | 3  | 1  |
| LYOPHILIZED      | 2 | 2 | 2 | 3 | 3 | 3 | 1 | 1 | 1 | 2  | 2  | 4  | 1  |
| SIGN TEST        | - | + |   |   | + | + |   |   |   |    |    | +  |    |

#### Inflammation - Clinical Evaluation

Inflammation evaluations of the wounds were determined by redness around the wound, pain, and other wound color changes. In no cases could a difference in inflammation be seen in areas of wounds covered by fresh heterograft when compared with areas covered by lyophilized heterografts (See Table 5).

#### Healing Time

The healing time of wounds vary with depth of wound and the patient's response to treatment. For this reason, it is not of concern that healing times ranged from six days to seventeen days. Fresh and freeze-dried pigskin were both applied to the same uniform wound in an effort to determine whether or not a particular wound would heal at a faster or slower rate beneath a certain type of pigskin. Pigskin was applied at different stages of wound healing ranging from the day of injury to postburn day nine, as necessitated by the degree of damaged tissue to be debrided before pigskin application. The entire wound was treated in the same manner, and when heterograft therapy was chosen, both fresh and lyophilized were applied.

TABLE 5  
CLINICAL INFLAMMATION ON SUBSEQUENT VISITS

| PATIENT              |             | A | B | C | C | D | D | E | E | F | G  | G  | H  | I  |
|----------------------|-------------|---|---|---|---|---|---|---|---|---|----|----|----|----|
| WOUND                |             | 1 | 2 | 3 | 4 | 5 | 6 | 7 | 8 | 9 | 10 | 11 | 12 | 13 |
| RETURN<br>VISIT<br>1 | GRAFT       |   |   |   |   |   |   |   |   |   |    |    |    |    |
|                      | FRESH       | 1 | 1 | 1 | 1 | 1 | 1 | 1 | 1 | 1 | 2  | 4  | 1  | 1  |
|                      | LYOPHILIZED | 1 | 1 | 1 | 1 | 1 | 1 | 1 | 1 | 1 | 2  | 4  | 1  | 1  |
|                      |             |   |   |   |   |   |   |   |   |   |    |    |    |    |
| RETURN<br>VISIT<br>2 | FRESH       | 1 | 1 | 1 | 1 | 1 | 1 | 1 | 1 | 1 | 1  | 3  | 1  | 1  |
|                      | LYOPHILIZED | 1 | 1 | 1 | 1 | 1 | 1 | 1 | 1 | 1 | 1  | 3  | 1  | 1  |
|                      |             |   |   |   |   |   |   |   |   |   |    |    |    |    |
|                      |             |   |   |   |   |   |   |   |   |   |    |    |    |    |
| RETURN<br>VISIT<br>3 | FRESH       | H | H | 1 | 1 | 1 | 1 | H | H | H | 1  | 3  | 1  | 1  |
|                      | LYOPHILIZED | H | H | 1 | 1 | 1 | 1 | H | H | H | 1  | 3  | 1  | 1  |
|                      |             |   |   |   |   |   |   |   |   |   |    |    |    |    |
|                      |             |   |   |   |   |   |   |   |   |   |    |    |    |    |
| RETURN<br>VISIT<br>4 | FRESH       | H | H | H | 1 | H | H | H | H | H | H  | 1  | H  | H  |
|                      | LYOPHILIZED | H | H | H | 1 | H | H | H | H | H | H  | 1  | H  | H  |
|                      |             |   |   |   |   |   |   |   |   |   |    |    |    |    |
|                      |             |   |   |   |   |   |   |   |   |   |    |    |    |    |

Inflammation Key

1 = no redness around burn  
 2 = pink edges extending less than .5 cm.  
 3 = pink to red area around burn from .5 to 2 cm.  
 4 = red, painful area around burn extending 2+ cm.  
 5 = red, painful area 2+ cm. around burn with color  
     changes within the wound  
 H = healed

Measurement of healing times proved to be difficult to evaluate. Because patients were not seen every single day, it was impossible to judge which day on a weekend the patients' burns healed. Similarly, two patients evidently reached a stage of healing with which they were satisfied and stopped coming to physical therapy before complete healing had occurred. On only three days could

a concrete judgment be made regarding the healing pattern of the wound. In one case (patient A), the wound was healed beneath the lyophilized on a particular day, and two days later, when seen again, was healed beneath the fresh pigskin. Therefore, it can only be said that the wound healed beneath the lyophilized skin one to two days faster than beneath the fresh pigskin. In patient C, wound 3, healing was complete beneath the lyophilized pigskin one day before it was complete beneath the fresh skin. In patient G, wound 10, healing beneath the fresh skin occurred between days six and nine; beneath the lyophilized skin by day ten. Application of the sign test once more shows two positive values and one negative, in other words, an insignificant difference in healing times (See Table 6).

#### Histologic Evaluation

Permission to take skin punch biopsies on two areas of the burn which healed beneath fresh and freeze-dried pigskin was granted by three patients (wounds 2, 7 and 13). In all three cases, evaluation by the department of dermatopathology revealed no significant differences in the tissue responses of the two specimens (See Appendix I).

#### Summary

In this series of studies in which fresh and lyophilized pigskin heterografts were applied to thirteen second-degree burn wounds in nine individuals, several aspects of healing have been evaluated

beneath each type of skin. Through the evaluation of bacterial contamination, adherence of the pigskin, number of applications of each type of skin which were necessary, inflammation, number of days healing time, and biopsies, an attempt was made to determine clinical superiority or inferiority of fresh or freeze-dried pigskin.

Due to the size of the population used in this study, no statistically significant conclusions may be drawn. Clinically, no clear preference for one or the other type of skin became evident from this study. In each individual comparison of healing aspects, no statistically significant difference could be seen between the performance of the two forms of skin. These results are suggestive of what might be seen in a larger, more controlled study. In the following chapter, the summary, conclusions, implications and recommendations drawn from this study will be presented.

TABLE 6

TIME FOR COMPLETE HEALING (DAYS)

| PATIENT<br>WOUND | A<br>1 | B<br>2 | C<br>3 | C<br>4 | D<br>5 | D<br>6 | E<br>7 | E<br>8 | F<br>9 | G<br>10 | G<br>11 | H<br>12 | I<br>13 |
|------------------|--------|--------|--------|--------|--------|--------|--------|--------|--------|---------|---------|---------|---------|
| GRAFT            |        |        |        |        |        |        |        |        |        |         |         |         |         |
| FRESH            | 6-8    | 7-10   | 17     | 17+    | 5+     | 5+     | 7      | 8      | 9-13   | 6-9     | 10      | 7-10    | 6-10    |
| LYOPHILIZED      | 4-6    | 7-10   | 16     | 17+    | 5+     | 5+     | 7      | 8      | 9-13   | 10      | 10      | 7-10    | 6-10    |
| SIGN TEST        | +      |        | +      |        |        |        |        |        |        | -       |         |         |         |

## CHAPTER V

### SUMMARY, CONCLUSIONS, IMPLICATIONS AND RECOMMENDATIONS

#### Summary

This study was undertaken to evaluate the healing of burn wounds beneath commercially processed fresh and lyophilized pigskin. Evaluation of levels of bacterial contamination, adherence of each form of heterograft, the number of applications of fresh and freeze-dried skin required before wound healing occurred, inflammation, days healing time, and biopsies of the healed burns were used as criteria by which to make comparisons. The population consisted of nine patients with three to fifteen percent total body surface area second-degree burns, being treated on an out-patient basis.

A review of literature revealed that the use of animal skin to protect open wounds has been an acceptable medical practice over the past century. Biologic dressings have been proven effective in protecting open wounds from water and protein losses, and in decreasing bacterial counts, cleaning up granulating tissue, decreasing pain and generally improving the patients state of well-being. Fresh pigskin, if handled as directed and used before the expiration date, is believed to be "alive," whereas lyophilized is known to be "dead" due to the nature of the irradiating and freeze-drying processes.



A review of the physiology of wound healing, and an explanation of the nurse's role in handling patient wounds with pigskin heterograft was also presented.

The patients used in this study were selected in a convenience sampling manner and all had small second-degree burns. Strips of fresh and lyophilized pigskin were placed on each wound, following the directions of the Burn Treatment Skin Bank. On each return visit to physical therapy the patients received hydrotherapy and the wounds were evaluated. Pigskin was reapplied to areas where the sloughing of the heterograft had occurred, with fresh pigskin over areas previously covered with fresh pigskin, and lyophilized pigskin over areas previously covered with lyophilized pigskin. Following healing of the wounds, biopsies of areas which healed beneath each type of skin were taken from consenting patients and evaluated by the department of dermatopathology.

Criteria consisting of bacterial colonization, adherence of heterograft, number of applications required of each type of heterograft, and amount of inflammation were evaluated on each visit. The number of days healing time and the biopsies obtained were also evaluated. Comparisons were made, between the ways the two types of heterograft performed on each wound. Analysis of the data was done using the sign test and averages, to bring out the differences in healing patterns.

Clinically no significant difference could be demonstrated between the performance of fresh and freeze-dried pigskin as it affected the previously mentioned criteria. However, due to the small population size of nine patients and thirteen wounds, no statistically significant conclusions may be drawn.

### Conclusions

From the data obtained from this series of case studies, the following conclusions were made:

1. The use of lyophilized pigskin heterograft as a substitute for fresh pigskin heterograft on second-degree burn wounds appears to be effective and deserves more study.
2. Until further study makes fresh pigskin preferable over freeze-dried pigskin, lyophilized pigskin may be the heterograft of choice in small hospitals where storage of fresh skin presents problems.

### Implications

The role of nurses involved in the care of the thermally injured patient is presently an expanding one. Burn nurses find themselves taking on new responsibilities previously considered to be the role of the physician. One of these added responsibilities

is that of applying, evaluating and caring for grafts, because of the necessity of observing the wounds on a day to day basis. The daily evaluations are most appropriately made by the nursing personnel who routinely change the dressings.

To adequately assess burn wounds, the nurse must understand the physiology of wound healing and the criteria by which healing is evaluated. The burn nurse clinical specialist should have the capability of evaluating the status of burn wounds and carries the responsibility for teaching and evaluating staff nurses in their observation skills. As members of the burn team immediately involved with wound care, burn nurses must understand the significance of grafting procedures, make pertinent observations and take appropriate action to enhance patient care.

Application of pigskin heterografts is a sterile procedure. It is interesting to note the inability of pigskin to decrease heavy bacterial growth in some cases, emphasizing the importance of handling the grafts with care and maintaining the wounds to minimize bacterial colonization.

Instructions for reconstitution of lyophilized pigskin vary from twenty minutes to one hour. Through pertinent observations on the effectiveness of grafts reconstituted for varying lengths of time, the nurse may contribute information which clarifies the reconstitution procedure.

It is important that wounds treated with heterograft be inspected daily or every other day. It was suggested by the data seen in this study that wounds which repeatedly slough pigskin day after day, often need to be cultured and treated with topical antibiotics before resuming heterograft application.

#### Recommendations

The use of lyophilized pigskin heterografts as a substitute for fresh pigskin heterografts would prove to be a valuable alternative in a hospital or clinic which treats burn patients only occasionally or in a hospital where storage of fresh pigskin poses a problem for some other reason. Based on this premise and the findings of this study, the following recommendations are made:

1. The study be repeated under more controlled conditions using in-patients so that wounds may be observed daily and more accurate evaluations of healing time may be obtained.
2. The study be extended over a longer period of time to include a larger population of burned patients.
3. Further evaluation of patients who demonstrate a definite preference for one type of skin or the other be carried out in an effort to identify characteristics which may predispose a particular patient to respond more favorably to a certain type of pigskin.

4. A study be conducted to identify optimal nursing procedure in reconstituting and applying lyophilized pigskin.
5. Studies be conducted to include comparisons of wound healing beneath frozen and frozen-irradiated pigskin. .

## LITERATURE CITED

### Books

- Brunner, Lillian Sholtis; Emerson, Charles Phillips; Ferguson, L. Kraeer; and Suddarth, Doris Smith. Textbook of Medical-Surgical Nursing, 2nd edition. New York:Lippincott, 1970.
- Feller, Irving and Archambeault, Claudella. Nursing the Burned Patient. Ann Arbor, Michigan: The Institute for Burn Medicine, 1973.
- Hunt, Thomas K. "Mechanisms of Repair and Spontaneous Healing." Contemporary Burn Management. Edited by H. Harlem Stone and Hiram C. Polk, Jr. Boston:Little, Brown and Company, 1971.
- Jacoby, Florence Greenhouse. Nursing Care of the Patient with Burns. Saint Louis:The C.V. Mosby Company, 1976.
- Law, E.J.; Nathan, P. and MacMillan, B.G. "Clinical Experience with Porcine Xenografts." Research in Burns. Vienna:Hans Huber and Barn Stuttgart,
- Luckmann, Joan and Sorensen, Karen Creason. Medical-Surgical Nursing: A Phychophysiologic Approach. Philadelphia:W.B. Saunders Company 1974.
- Polk, Hiram C. and Stone, H. Harlan. "Pseudomonas and Other Gram-negative Bacteria." Contemporary Burn Management. Boston:Little, Brown and Company, 1971.
- Pruitt, Basil A. and Curreri, P. William. "The Use of Homograft and Heterograft Skin." Contemporary Burn Management. Edited by H. Harlan Stone and Hiram C. Polk, Jr. Boston:Little, Brown and Company, 1971.
- Shafer, Kathleen N.; Sawyer, Janet R.; McCluskey, Audrey M.; Beck, Edna L.; and Phipps, Wilma J. Medical-Surgical Nursing, 5th edition. New York:The C.V. Mosby Company, 1971.

### Journals

- Abbott, William M., and Pappas, Arthur M. "Comparative Studies on Fresh and Preserved Skin: Fundamental Biologic Differences in Behavior as Grafts," Annals of Surgery 172 (1970):781.

- Artz, Curtis P.; Rittenbury, Max S.; and Yarbrough, Dabney R. "An Appraisal of Allografts and Xenografts as Biologic Dressings for Wounds and Burns," Annals of Surgery 175 (1972):934.
- Baxter, Charles R. "Homografts and Heterografts as a Biologic Dressing in the Treatment of Thermal Injury," Proceedings of the First Annual Congress of the Society of German Plastic Surgeons Munich, 1970.
- Bertke, E.M.; Sheppard, E. Patricia; Reichenbacher, F.W. "Histology of Fresh Porcine Skin Xenografts," Burn Treatment Skin Bank, Inc. 1972.
- Bondoc, C.C. and Burke, J.F. "Clinical Experience With Viable Frozen Human Skin and a Frozen Skin Bank," Annals of Surgery 174 (1971):371.
- Bromberg, Bertram E. "Burn Wound Management With Biologic Dressings," New York State Journal of Medicine 70 (1970):1645.
- Bromberg, B.E. and Song, I.C. "Pigskin Heterografts," Minnesota Medicine 48 (1965):1605.
- Bromberg, Bertram E. and Song, In Chul. "Skin Substitutes, Homo-, and Heterografts," The American Journal of Surgery 112 (1966):28.
- Bromberg, Bertram E.; Song, In Chul; and Mohn, Melvin P. "The Use of Pig Skin as a Temporary Biologic Dressing," Plastic and Reconstructive Surgery 36 (1965):80.
- Burleson, R. and Eiseman, B. "Mechanisms of Antibacterial Effect of Biologic Dressings," Annals of Surgery 177 (1973):181.
- Burn Treatment Skin Bank, Inc. Information booklet, 1973.
- Chang, Wallace H.J.; Gomez, Nery H.; and Edelstein, Leon M. "Use of Lyophilized Pig Skin for Donor Site Cover," British Journal of Plastic Surgery 26 (1973):147.
- Converse, John Marquis and Rapaport, Felix T. "The Vascularization of Skin Autografts and Homografts; An Experimental Study in Man," Annals of Surgery 113 (1956):306.
- Eade, G.C. "The Relationship Between Granulation Tissue, Bacteria, and Skin Grafts in Burned Patients," Plastic and Reconstructive Surgery 22 (1958):42.
- Georgiade, N.; Peschel, E.; Georgiade, R.; and Brown, I. "A Clinical and Experimental Investigation of the Preservation of Skin," Plastic and Reconstructive Surgery 17 (1956):267.

- Elliott, Ray A. and Hoehn, James G. "The Use of Commercial Porcine Skin for Wound Dressings," Plastic and Reconstructive Surgery 52 (1973):401.
- Georgiade, N.; Peschel, E.; Georgiade, R.; and Brown, I. "A Clinical and Experimental Investigation of the Preservation of Skin," Plastic and Reconstructive Surgery 17 (1956):267.
- German, John C.; Wooley, Telford E.; Achauer, Bruce; Furnas, David W.; and Bartlett, Robert H. "Porcine Xenograft Burn Dressings," Archives of Surgery 104 (1972):806.
- Graham, William P.; Hamilton, Ralph W.; and Lehr, Herndon B. "Versatility of Skin Allografts: Desirability of a Viable Frozen Tissue Bank," The Journal of Trauma 11 (1971):494.
- Hackett, M. and Bowen, J. "Preliminary Report on the Comparative Use of Lyophilized Homograft and Xenograft in the Closure of Raw Areas," British Journal of Surgery 61 (1974):427.
- Harris, Nick S. and Abston, Sally. "Anti-Porcine Antibodies in Xenografted Burned Patients," Journal of Surgical Research 16 (1974):599.
- Hunt, John L.; McGranahan, Betty G.; and Pruitt, Basil A. "Burn Wound Management," Heart and Lung 2 (1973):690.
- Hyatt, G.W.; Turner, T.C.; Bassett, C.A.L.; Pate, J.W. and Sawyer, P.N. "New Methods for Preserving Bone, Skin and Blood Vessels," Graduate Medicine (1959).
- Lawrence, J.C. "Storage and Skin Metabolism," British Journal of Plastic Surgery 25 (1972):440.
- Ledgerwood, Anna M. and Lucas, Charles E. "Role of Porcine Skin Grafting of Exposed Arterial Vein Grafts," Archives of Surgery 107 (1973):201.
- Lee, Yen-Ching. "Early Heterografting of Partial-Thickness Burns," The Journal of Trauma 12 (1972):818.
- Mast, Jeffrey. "Porcine Dressings in the Management of Ulcers and Skin," Presented at the Orthopedic Conference, Rancho Los Amigos Hospital, 1972.



- McCabe, W. Peter; Rebuck, John W.; Kelly, Alex P.; and Ditmars, Donald M. "Cellular Immune Response of Humans to Pigskin," Plastic and Reconstructive Surgery 51 (1973):181.
- Miller, Timothy A.; Switzer, Walter E.; Foley, F.D.; and Moncrief, John A. "Early Homografting of Second Degree Burns," Plastic and Reconstructive Surgery 40 (1967):117.
- Minckley, Barbara B. "Expert Nursing Care," American Journal of Nursing, 70 (1970):1888.
- Moncrief, John A. "Burns," The New England Journal of Medicine 228 (1973):444.
- Morris, Peter J.; Bondoc, C.; and Burke, John F. "The Use of Frequently Changed Skin Allografts to Promote Healing in the Nonhealing Infected Ulcer," Surgery 60 (1966):13.
- Nathan, Paul; Holder, Ian Alan; and MacMillan, Bruce G. "Burn Wounds: Microbiology, Local Host Defenses, and Current Therapy," CRC Critical Reviews in Clinical Laboratory Sciences 4 (1973):61.
- Newsom, Hamlet T.; Salyer, Kenneth E.; and Baxter, Charles R. "The Use of Heterografts in Acute Burns," Presented at Meeting of Plastic and Reconstructive Surgery, Miami, 1971.
- O'Neill, James A. "Comparison of Xenograft and Prosthesis for Burn Wound Care," Journal of Pediatric Surgery 8 (1973):705.
- Pandya, Narendra J. and Zarem, Harvey A. "The Absence of Vascularization in Porcine Skin Grafts on Mice," Plastic and Reconstructive Surgery 53 (1974):211.
- Pruitt, Basil A. and Silverstein, Paul. "Methods of Resurfacing Denuded Skin Areas," Transplantation Proceedings 3 (1971):1537.
- Rapaport, I.; Pepino, A.T.; and Dietrick, William. "Early Use of Xenografts as a Biologic Dressing in Burn Trauma," The American Journal of Surgery 120 (1970):144.
- Robbins, Irene. "Care of the Burned Ear."
- Rogers, Blair Oakley. "Historical Development of Free Skin Grafting," Surgical Clinics of North America 39 (1959):289.

- Salisbury, Roger E.; Wilmore, Douglas W.; Silverstein, Paul; and Pruitt, Basil A. "Biological Dressings for Skin Graft Donor Sites," Archives of Surgery 106 (1973):705.
- Santoni-Rugiu, Paolo. "Compared Studies on the Viability of Skin Stored by Different Methods," Plastic and Reconstructive Surgery 30 (1962):586.
- Sayman, Dennis G.; Nathan, Paul; Holder, Ian Alan; Hill, Edward O.; and MacMillan, Bruce G. "Control of Surface Wound Infection: Skin Versus Synthetic Grafts," Applied Microbiology 25 (1973):921.
- Sewell, William H.; Koth, Douglas R.; Pate, James W.; and Bedell, Wallace C. "Review of Some Experiments with Freeze-Dried Grafts," American Journal of Surgery 91 (1956):358.
- Shuck, Jerry M.; Pruitt, Basil A.; and Moncrief, John A. "Homograft Skin for Wound Coverage," Archives of Surgery 98 (1969):472.
- Silverstein, Paul; Curreri, P. William, and Munster, Andrew M. "Clinical and Immunological Evaluation of Frozen, Electron-Beam Irradiated Porcine Xenograft as a Skin Substitute," Brooke Army Medical Center - Final Report (1971).
- Silverstein, Paul; Warden, Glenn D.; Salisbury, Roger E.; and McManus, William F. "Continued Evaluation of Split-thickness Cutaneous Xenograft as a Temporary Biologic Wound Cover for Use in Burned Soldiers," Brooke Army Medical Center - Annual Progress Report (1972).
- Skoog, Tord. "An Experimental and Clinical Investigation of the Effect of Low Temperature on the Viability of Excized Skin," Plastic and Reconstructive Surgery 14 (1954):403.
- Smith, Richard T. "The Mechanism of Graft Rejection," Clinical Orthopaedics and Related Research (1972):15.
- Song, In Chul; Bromberg, Bertram E.; Mohn, Melvin P.; and Koehnlein, Edzard, "Heterografts as Biologic Dressings for Large Skin Wounds," Surgery 59 (1966):576.
- State, David and Peter, Michael E. "Clinical Use of Porcine Xenografts in Conditions other than Burns," Surgery, Gynecology and Obstetrics 138 (1974):13.

Stinson, Velda. "Porcine Skin Dressings for Burns," American Journal of Nursing 74 (1974):111.

Teplitz, C.; Davis, D.; Mason, A.D.; and Moncrief, J.A. "Pseudomonas Burn Wound Sepsis," Journal of Surgical Research 4 (1964):200.

Toranto, I. Richard; Salyer, Kenneth E.; and Myers, M. Bert.  
"Vascularization of Porcine Skin Heterografts," Plastic and Reconstructive Surgery 54 (1974):195.

Wood, MacDonald and Hale, Harry W. "The Use of Pigskin in the Treatment of Thermal Burns," The American Journal of Surgery 124 (1972):720.

Young, J.M. and Hyatt, G.W. "Stored Skin Homografts in Extensively Burned Patients," A.M.A. Archives of Surgery 80 (1969):40/208.

Zawacki, Bruce E. "Reversal of Capillary Stasis and Prevention of Necrosis in Burns," Annals of Surgery 180 (1974):98.

## BIBLIOGRAPHY

### Books

- Baxter, Charles R. "Burns." Current Therapy. Philadelphia: W.B. Saunders, 1967.
- Beland, Irene and Passos, Irene. Clinical Nursing: Pathophysiological and Psychosocial Approaches, 3rd edition. New York:MacMillan Publishing Company, Inc., 1975.
- Brunner, Lillian Sholtis; Emerson, Charles Phillips; Ferguson, L. Kraeer; and Suddarth, Doris Smith. Textbook of Medical-Surgical Nursing, 2nd edition. New York:Lippincott, 1970.
- Feller, Irving and Archambeault, Claudella. Nursing the Burned Patient. Ann Arbor, Michigan:The Institute for Burn Medicine, 1973.
- Gordon, Benjamin Lee and Ford, Denys K. Essentials of Immunology. Philadelphia:F.A. Davis Company, 1971.
- Hunt, Thomas K. "Mechanisms of Repair and Spontaneous Healing." Contemporary Burn Management. Edited by H. Harlan Stone and Hiram C. Polk, Jr. Boston:Little, Brown and Company, 1971.
- Jacoby, Florence Greenhouse. Nursing Care of the Patient with Burns. Saint Louis:C.V. Mosby Company, 1976.
- Larson, Duane L. "Biologic Dressings for Burn Wounds." Symposium of the Treatment of Burns, edited by J.B. Lynch and Stephen R. Lewis. St. Louis:C.V. Mosby Company, 1973.
- Law, E.J.; Nathan P. and MacMillan, B.G. "Clinical Experiences with Porcine Xenografts." Research in Burns. Vienna: Hans Huber and Barn Stuttgart, 1971.
- Luckmann, Joan and Sorenson, Karen Creason. Medical-Surgical Nursing: A Phychophysiologic Approach. Philadelphia: W.B. Saunders Company, 1974.
- Muir, I.F.K. and Barclay, T.L. Burns and Their Treatment. Chicago:Yearbook Medical Publishers, Inc., 1974.



- Polk, Hiram C. and Stone, H. Harlan. "Pseudomonas and Other Gram-negative Bacteria." Contemporary Burn Management. Boston:Little, Brown and Company, 1971.
- Pruitt, Basil A. and Curreri, P. William. "The Use of Homograft and Heterograft Skin." Contemporary Burn Management. Edited by H. Harlan Stone and Hiram C. Polk, Jr. Boston: Little, Brown and Company, 1971.
- Shafer, Kathleen N.; Sawyer, Janet R.; McCluskey, Audrey M.; Beck, Edna L.; and Phipps, Wilma J. Medical-Surgical Nursing, 5th edition. New York:C.V. Mosby Company, 1971.
- Stone, Nelson H. and Boswick, John A. Profiles of Burn Management. Miami, Florida:Industrial Medicine Publishing Company, Inc., 1969.

#### Journals

- Abbott, William M. and Pappas, Arthur M. "Comparative Studies on Fresh and Preserved Skin: Fundamental Biologic Differences in Behavior as Grafts," Annals of Surgery 172 (1970):781.
- Allen, Hoyt E.; Edgerton, Milton T.; Rodeheaver, George T.; Prusak, Margaret P.; Kurtz, Leonard D.; and Edlich, Richard F. "Skin Dressings in the Treatment of Contaminated Wounds," The American Journal of Surgery 126 (1973):45.
- Artz, Curtis P.; Rittenbury, Max S.; and Yarbrough, Dabney R. "An Appraisal of Allografts and Xenografts as Biologic Dressings for Wounds and Burns," Annals of Surgery 175 (1972):934.
- Athreya, Balu H.; Grimes, E.L.; Lehr, Herndon B.; Greene, Arthur E.; and Coriell, Lewis L. "Differential Susceptibility of Epithelial Cells and Fibroblasts of Human Skin to Freeze Injury," Cryobiology 5 (1969):262.
- Baxter, Charles R. "Homografts and Heterografts as a Biologic Dressing in the Treatment of Thermal Injury," Proceedings of the First Annual Congress of the Society of German Plastic Surgeons Munich, 1970.
- Belitsky, Philip; Popovtzer, Mordecai; Corman, Jacques; Launois, Bernard; and Porter, Kendrick. "Modification of Hyperacute Xenograft Rejection by Intra-Arterial Infusion of Disodium Ethylenediaminetetraacetate," Transplantation 15 (1973):248.

- Bertke, E.M.; Sheppard, E. Patricia; Reichenbacher, F.W. "Histology of Fresh Porcine Skin Xenografts," Burn Treatment Skin Bank, Inc. 1972.
- Bondoc, C.C. and Burke, J.F. "Clinical Experience With Viable Frozen Human Skin and a Frozen Skin Bank," Annals of Surgery 174 (1971):371.
- Bromberg, Bertram E. "Burn Wound Management with Biologic Dressings," New York State Journal of Medicine 70 (1970):1645.
- Bromberg, B.E. and Song, I.C. "Pigskin Heterografts," Minnesota Medicine 48 (1965):1605.
- Bromberg, Bertram E. and Song, In Chul. "Skin Substitutes, Homo-, and Heterografts," The American Journal of Surgery 112 (1966):28.
- Bromberg, Bertram E., Song, In Chul; and Mohn, Melvin P. "The Use of Pig Skin as a Temporary Biologic Dressing," Plastic and Reconstructive Surgery 36 (1965):80.
- Brucker, Walter L. and Longmire, William P. "Wound Healing: A Local Reaction or a Systemic Process?" Journal of Surgical Research 9 (1969):279.
- Burke, J.F.; Quinby, W.C.; Bondoc, C.C.; Cosimi, A.B.; Russell, P.S.; and Szyfelbein, S.K. "Immunosuppression and Temporary Skin Transplantation in the Treatment of Massive Third Degree Burns," Annals of Surgery 182 (1975):183.
- Burleson, R. and Eiseman, B. "Effect of Partial Thickness Skin Dressings, Sulfamylon, Silver Sulfadiazine, and Sepsis on Healing of Partial Thickness Wounds in Rats," December, 1971.
- Burleson, R. and Eiseman, B. "Mechanisms of Antibacterial Effect of Biologic Dressings," Annals of Surgery 177 (1973):181.
- Burleson, R. and Eiseman, B. "Nature of the Bond Between Partial-Thickness Skin and Wound Granulations," Surgery 72 (1972):315.
- Burn Treatment Skin Bank, Inc. Information booklet, 1973.
- Chambler, K. and Sach, A. "The Use of Etox Lyophilized Skin in Burns," British Journal of Plastic Surgery 22 (1969):210.
- Chang, Wallace H.J.; Gomez, Nery H.; and Edelstein, Leon M. "Use of Lyophilized Pig Skin for Donor Site Cover," British Journal of Plastic Surgery 26 (1973):147.

- Converse, John Marquis and Rapaport, Felix T. "The Vascularization of Skin Autografts and Homografts; An Experimental Study in Man," Annals of Surgery 113 (1956):306.
- Creech, Brevator J.; DeVito, Robert V.; and Eade, Gilbert G. "Viability of Split-skin Grafts from Pigs following Incubation on Autologous Blood or Serum for Various Periods," Plastic and Reconstructive Surgery 51 (1973):572.
- Eade, G.C. "The Relationship Between Granulation Tissue, Bacteria, and Skin Grafts in Burned Patients," Plastic and Reconstructive Surgery 22 (1958):42.
- Elliott, Ray A. and Hoehn, James G. "The Use of Commercial Porcine Skin for Wound Dressings," Plastic and Reconstructive Surgery 52 (1973):401.
- Entin, Martin A.; Baxter, Hamilton; and More, Robert H. "Experimental and Clinical Studies of Reduced Temperatures in Injury and Repair in Man," Plastic and Reconstructive Surgery 3 (1948):11.
- Flatt, Adrian E. "Observations on the Growth of Refrigerated Skin Grafts," British Journal of Plastic Surgery 3 (1959):28.
- Freeman, Aaron, E.; Igel, Howard J.; Waldman, Neil L.; and Losikoff, Andrew M. "A New Method for Covering Large Surface Area Wounds with Autografts," Archives of Surgery 108 (1974):721.
- Friedman, Gary D.; Capozzi, Angelo; and Pennisi, Vincent R. "Care of the Split-thickness Skin Graft Donor Site," Journal of Trauma 14 (1974):163.
- Georgiade, N.; Peschel, E.; Georgiade, R.; and Brown, I. "A Clinical and Experimental Investigation of the Preservation of Skin," Plastic and Reconstructive Surgery 17 (1956):267.
- German, John C.; Wooley, Telford E.; Achauer, Bruce; Furnas, David W.; and Bartlett, Robert H. "Porcine Xenograft Burn Dressings," Archives of Surgery 104 (1972):806.
- Graham, William P. "Allografting Split-thickness Skin Donor Sites," Surgery 66 (1969):460.
- Graham, William P.; Hamilton, Ralph W.; and Lehr, Herndon B. "Versatility of Skin Allografts: Desirability of a Viable Frozen Tissue Bank," The Journal of Trauma 11 (1971):494.



- Habal, Mutaz B. "A Short Note on the Physiologic Response to the Cutaneous Xenograft as a Biologic Dressing," Current News and Comment 14 (1974):94.
- Hackett, M. and Bowen, J. "Preliminary Report on the Comparative Use of Lyophilized Homograft and Xenograft in the Closure of Raw Areas," British Journal of Surgery 61 (1974):427.
- Harris, Nick S. and Abston, Sally. "Anti-Porcine Antibodies in Xenografted Burned Patients," Journal of Surgical Research 16 (1974):599.
- Hindshaw, J. Raymond and Miller, Edgar R. "Histology of Healing Split-Thickness, Full-Thickness Autogenous Skin Grafts and Donor Sites," Archives of Surgery 91 (1965):658.
- Hunt, John L.; McGranahan, Betty G.; and Pruitt, Basil A. "Burn Wound Management," Heart and Lung 2 (1973):690.
- Hunt, John L. and Pruitt, Basil A. "Management of Thermal Injury," (To be published)
- Hyatt, G.W.; Turner, T.C.; Bassett, C.A.L.; Pate, J.W.; and Sawyer, P.N. "New Methods for Preserving Bone, Skin, and Blood Vessels," Graduate Medicine (1959).
- King, Michael H.; Heimbecker, Raymond O.; and Trimble, Alan S. "Importance of Technique in Preserving Human Aortic Valves," Surgical Forum (1967):119.
- Lawrence, J.C. "Storage and Skin Metabolism," British Journal of Plastic Surgery 25 (1972):440.
- Ledgerwood, Anna M. and Lucas, Charles E. "Role of Porcine Skin Grafting of Exposed Arterial Vein Grafts," Archives of Surgery 107 (1973):201.
- Ledgerwood, Anna and Lucas, Charles E. "Split Thickness Porcine Graft in the Treatment of Close-Range Shotgun Wounds to Extremities with Vascular Injury," The American Journal of Surgery 125 (1973):690.
- Lee, Yen-Ching. "Early Heterografting of Partial-Thickness Burns," The Journal of Trauma 12 (1972):818.
- MacMillan, Bruce G. "Homograft Skin - A Valuable Adjunct to the Treatment of Thermal Burns," Presented at the Twenty-first Annual Session of the American Association for the Surgery of Trauma, 1961.



- Mast, Jeffrey. "Porcine Dressings in the Management of Ulcers of Skin," Presented at the Orthopedic Conference, Rancho Los Amigos Hospital, 1972.
- McCabe, W. Peter; Rebuck, John W.; Kelly, Alex P.; and Ditmars, Donald M. "Cellular Immune Response of Humans to Pigskin," Plastic and Reconstructive Surgery 51 (1973):181.
- McCormack, Robert M. "Viability Studies of Human Skin Grafts as Determined by Tissue Culture Methods," Plastic and Reconstructive Surgery 19 (1957):483.
- Medawar, P.B. "The Storage of Living Skin," Proceedings of the Royal Society of Medicine (1953):62.
- Miller, Timothy A.; Switzer, Walter E.; Foley, F.D.; and Moncrief, John A. "Early Homografting of Second Degree Burns," Plastic and Reconstructive Surgery 40 (1967):117.
- Minckley, Barbara B. "Expert Nursing Care," American Journal of Nursing 70 (1970):1888.
- Moncrief, John A. "Burns," The New England Journal of Medicine 288 (1973):444.
- Morris, Peter J.; Bondoc, C.; and Burke, John F. "The Use of Frequently Changed Skin Allografts to Promote Healing in the Nonhealing Infected Ulcer," Surgery (1966):13.
- Nathan, Paul; Holder, Ian Alan; and MacMillan, Bruce G. "Burn Wounds: Microbiology, Local Host Defenses, and Current Therapy," CRC Critical Reviews in Clinical Laboratory Sciences 4 (1973):61.
- Nathan, Paul; MacMillan, Bruce G.; and Holder, Ian A. "Effect of a Synthetic Dressing Formed on a Burn Wound in Rats: A Comparison of Allografts, Collagen Sheets, and Polyhydroxyethylmethacrylate in the Control of Wound Infection," Applied Microbiology 28 (1974):465.
- Newsom, Hamlet T.; Salyer, Kenneth E.; and Baxter, Charles R. "The Use of Heterografts in Acute Burns," Presented at the Meeting of Plastic and Reconstructive Surgery, Miami, 1971.

- O'Neill, James A. "Comparison of Xenograft and Prosthesis for Burn Wound Care," Journal of Pediatric Surgery 8 (1973):705.
- O'Neill, James A. Grosfeld, Jay L.; and Boles, E. Thomas. "The Extended Use of Skin Homografts," Archives of Surgery 99 (1969):263.
- Pandya, Narendra J. and Zarem, Harvey A. "The Absence of Vascularization in Porcine Skin Grafts on Mice," Plastic and Reconstructive Surgery 53 (1974):211.
- Polk, Hiram C. "Prolongation of Xenograft Survival in Patients with Pseudomonas Sepsis: A Clarification," Plastic Surgery 514 (1968):514.
- Pruitt, Basil A. and Silverstein, Paul. "Method of Resurfacing Denuded Skin Areas," Transplantation Proceedings 3 (1971):1537.
- Rapaport, I.; Pepino, A.T.; and Dietrick, William. "Early Use of Xenografts as a Biologic Dressing in Burn Trauma," The American Journal of Surgery 120 (1970):144.
- Robbins, Irene. "Care of the Burned Ear."
- Robson, Martin C. and Krizek, Thomas J. "Predicting Skin Graft Survival," The Journal of Trauma 13 (1973):213.
- Rogers, Blair Oakley. "Historical Development of Free Skin Grafting," Surgical Clinics of North America 39 (1959):289.
- Salisbury, Roger E.; Wilmore, Douglas W; Silverstein, Paul; and Pruitt, Basil A. "Biological Dressings for Skin Graft Donor Sites," Archives of Surgery 106 (1973):705.
- Salisbury, Roger E.; Hunt, John L.; Warden, Glenn D.; and Pruitt, Basil A. "Management of Electrical Burns of the Upper Extremity," Plastic and Reconstructive Surgery 51 (1973):648.
- Santoni-Rugiu, Paolo. "Compared Studies on the Viability of Skin Stored by Different Methods," Plastic and Reconstructive Surgery 30 (1962):586.
- Sawhney, C.P.; Subbaraju, G.V.; and Chakravarti, R.N. "Healing of Donor Sites of Split Thickness Grafts," British Journal of Plastic Surgery (1970):359.

- Saymen, Dennis G.; Nathan, Paul; Holder, Ian Alan; Hill, Edward O.; and MacMillan, Bruce G. "Control of Surface Wound Infection: Skin Versus Synthetic Grafts," Applied Microbiology 25 (1973):921.
- Scott, H. William; Collins, Harold A.; and Foster, John H. "Clinical Experience with Arterial Homografts Sterilized with Ethylene Oxide and Preserved by the Freeze-Dry Method," Journal of the Tennessee State Medical Association 48 (1955):435.
- Sewall, William H.; Koth, Douglas R.; Pate, James W.; and Bedell, Wallace C. "Review of Some Experiments with Freeze-Dried Grafts," American Journal of Surgery 91 (1956):358.
- Sheppard, E.P. and Reichenbacher, F.W. "Structure of Several Forms of Porcine Skin," Burn Treatment Skin Bank, Inc.
- Shuck, Jerry M.; Pruitt, Basil A.; and Moncrief, John A. "Homograft Skin for Wound Coverage," Archives of Surgery 98 (1969):472.
- Silverstein, Paul; Warden, Glenn D.; McManus, William F.; and Walker, Harrell L. "A Study of Immune Response to Split-Thickness Cutaneous Xenograft to Improve Care of Burn Wounds in Military Personnel," Brooke Army Medical Center - Final Report (1972).
- Silverstein, Paul; Curreri, P. William; and Munster, Andrew M. "Clinical and Immunological Evaluation of Frozen, Electron-Beam Irradiated Porcine Xenograft as a Skin Substitute," Brooke Army Medical Center - Final Report (1971).
- Silverstein, Paul; Warden, Glenn D.; Salisbury, Roger E.; and McManus, William F. "Continued Evaluation of Split-Thickness Cutaneous Xenograft as a Temporary Biologic Wound Cover for Use in Burned Soldiers," Brooke Army Medical Center - Annual Progress Report (1972).
- Silverstein, Paul; Curreri, P. William; and Munster, Andrew M. "Evaluation of Fresh, Viable Porcine Cutaneous Xenograft as a Temporary Burn Wound Cover," Brooke Army Medical Center - Annual Progress Report (1971).
- Skoog, Tord. "An Experimental and Clinical Investigation of the Effect of Low Temperature on the Viability of Excized Skin," Plastic and Reconstructive Surgery 14 (1954):403.



- Smith, Richard T. "The Mechanisms of Graft Rejection," Clinical Orthopaedics and Related Research (1972):15.
- Song, In Chul; Bromberg, Bertram E.; Mohn, Melvin P.; and Koehnlein, Edzard. "Heterografts as Biologic Dressings for Large Skin Wounds," Surgery 59 (1966):576.
- Song, In Chul; Koehnlein, Edzard; and Mohn, Melvin P. "Pigskin and Bovine Collagen as Possible Temporary Dressings for Skin Wounds," Surgical Forum.
- State, David and Peter, Michael E. "Clinical Use of Porcine Xenografts in Conditions other than Burns," Surgery, Gynecology and Obstetrics 138 (1974):13.
- Stinson, Velda. "Porcine Skin Dressings for Burns," American Journal of Nursing 74 (1974):111.
- Switzer, Walter E.; Moncrief, John A.; Mills, William; Order, Stanley E.; and Lindberg, Robert B. "The Use of Canine Heterografts in the Therapy of Thermal Injury," The Journal of Trauma 6 (1966):391.
- Taylor, A. Cecil and Gerstner, Robert. "Tissue Survival after Exposure to Low Temperatures and the Effectiveness of Protective Pretreatments," Journal of Cellular and Comparative Physiology 46 (1955):477.
- Teplitz, C.; Davis, D.; Mason, A.D.; and Moncrief, J.A. "Pseudomonas Burn Wound Sepsis," Journal of Surgical Research 4 (1964):200.
- Toronto, I. Richard; Salyer, Kenneth E.; and Myers, M. Bert. "Vascularization of Porcine Skin Heterografts," Plastic and Reconstructive Surgery 54 (1974):195.
- Webster, Jerome P. "Refrigerated Skin Grafts," Annals of Surgery 120 (1944):431.
- Wood, MacDonald and Hale, Harry W. "The Use of Pigskin in the Treatment of Thermal Burns," The American Journal of Surgery 124 (1972):720.
- Young, J.M. and Hyatt, G.W. "Stored Skin Homografts in Extensively Burned Patients," A.M.A. Archives of Surgery 80 (1960):40/208.
- Zawacki, Bruce E. "Reversal of Capillary Stasis and Prevention of Necrosis in Burns," Annals of Surgery 180 (1974):98.

TEXAS WOMAN'S UNIVERSITY  
COLLEGE OF NURSING  
DENTON, TEXAS

DALLAS CENTER  
1810 Inwood Road  
Dallas, Texas 75235

HOUSTON CENTER  
1130 M.D. Anderson Blvd.  
Houston, Texas 77025

AGENCY PERMISSION FOR CONDUCTING STUDY\*

THE Dallas County Hospital District  
GRANTS TO Elizabeth A. Delwig, R.N., B.S.

a student enrolled in a program of nursing leading to a Master's Degree at Texas Woman's University, the privilege of its facilities in order to study the following problem:

The conditions mutually agreed upon are as follows:

1. The agency (may) (~~may not~~) be identified in the final report.
2. The names of consultative or administrative personnel in the agency (may) (~~may not~~) be identified in the final report.
3. The agency (~~wants~~) (does not want) a conference with the student when the report is completed.
4. The agency is (willing) (~~unwilling~~) to allow the completed report to be circulated through interlibrary loan.

5. Other: Stated like a copy of the  
Findings

Date

July 30, 1975

Elizabeth A. Delwig  
Signature of Agency Personnel

Elizabeth A. Delwig, RN  
Signature of student

Margalene Lopez R.N., M.S.  
Signature of Faculty Advisor

\*Fill out and sign three copies to be distributed as follows: Original -- Student; first copy -- agency; second copy -- T.W.U. College of Nursing.

APPENDIX B-1  
TEXAS WOMAN'S UNIVERSITY  
DALLAS, TEXAS 75235

October 24, 1975

COLLEGE OF NURSING

Elizabeth Helvig  
Texas Woman's University  
1810 Inwood Rd.  
Dallas, Texas 75235

Dear Ms. Helvig:

The Human Research Review Committee has reviewed and approved your protocol,  
"Healing of Burns in Response to Pigskin Heterografts."

Sincerely,

*Lois Hough*  
*by Opal H. White*  
Lois Hough, Chairman  
Human Research Review Committee

APPENDIX B-2  
THE UNIVERSITY OF TEXAS  
HEALTH SCIENCE CENTER AT DALLAS  
Southwestern Medical School

DEPARTMENT OF INTERNAL MEDICINE

5323 HARRY HINES BOULEVARD  
DALLAS, TEXAS 75235  
TELEPHONE (214) 688-3486

October 1, 1975

Charles R. Baxter, M.D.  
Department of Surgery

Dear Dr. Baxter:

The Human Research Review Committee has approved your request for a study entitled "Healing of Burns in Response to Pigskin Heterografts".

The Committee asked me to remind you that both the University and the Department of Health, Education and Welfare regulations require that written consents must be obtained from all human subjects in your studies. These consent forms must be kept on file for a period of three years past completion or discontinuation of the study and will no doubt be subject to inspection in the future.

Furthermore, we have been directed to review any change in research procedure that you might find necessary. In other words, should your project change, another review by the Committee is required, according to DHEW regulations.

Sincerely,

*J. Donald Smiley, M.D.*

J. Donald Smiley, M.D.  
Chairman  
Human Research Review Committee

ah



APPENDIX C

SUBJECT \_\_\_\_\_ Out-patient  
\_\_\_\_\_ In-patient Unit \_\_\_\_\_

Fresh and freeze-dried pigskin have been proven to be safe and effective treatments for burned patients. Pigskin is used routinely at Parkland both to provide comfort and to speed healing of burn wounds. This study is being done in an effort to look more closely at how these two forms of skin compare with each other in helping healing. Photographs of the burn wound will be used to show the progress of healing. Cultures will be taken routinely to insure proper management of the burn wound. Finally, on two occasions, when the burn is healed, the wound will be numbed with medication and a small sample of tissue will be taken to be looked at under a microscope. When the medication wears off, there may be a small amount of discomfort from the biopsy site, but it should heal quickly on its own.

I have read the above statement and it has been explained to me that this is an investigational study. I understand that I may withdraw my consent for my (his, her) further participation as a subject at any time without affecting my (his, her) status as a patient. With my understanding of this, having received this information and satisfactory answers to the questions I have asked, I voluntarily consent to the procedure and treatment designated above.

I hereby give my consent to Charles R. Baxter, M.D. and/or Elizabeth Helvig, R.N. to perform or supervise the following investigational procedures and treatment:

The taking of photographs of the burn wound  
Culturing the wound as necessary to monitor the bacteria  
Two biopsies of the healed burn

on \_\_\_\_\_  
NAME OF SUBJECT DATE

SIGNED: \_\_\_\_\_ WITNESS: \_\_\_\_\_

\_\_\_\_\_  
RELATIONSHIP WITNESS: \_\_\_\_\_

Instructions as to persons authorized to sign:

If the subject is not competent, the person responsible shall be the legal appointed guardian or the nearest of kin.

If the subject is a minor under 21 years of age, the person responsible is the mother or father or legally appointed guardian.

If the subject is unable to write his name, the following is legally acceptable: John H. (His X Mark) Doe and two (2) witnesses.



PIGSKIN STUDY

Date \_\_\_\_\_

Patient Information Sheet

Patient's name \_\_\_\_\_ Date burned \_\_\_\_\_

Age (10-65) \_\_\_\_\_ Type burn \_\_\_\_\_

Area used in study \_\_\_\_\_ Total burn 2nd° \_\_\_\_\_

3rd° \_\_\_\_\_

TBSA (3-20%) \_\_\_\_\_

MEDICAL HISTORY -- has patient had:

check if

"Yes"

Year

\_\_\_\_\_ Heart disease \_\_\_\_\_  
\_\_\_\_\_ Syphilis \_\_\_\_\_  
\_\_\_\_\_ Diabetes \_\_\_\_\_  
\_\_\_\_\_ Kidney disease \_\_\_\_\_  
\_\_\_\_\_ Stasis ulcers \_\_\_\_\_  
\_\_\_\_\_ Stroke \_\_\_\_\_  
\_\_\_\_\_ Anemia \_\_\_\_\_

check if

"Yes"

Year

\_\_\_\_\_ Emphysema \_\_\_\_\_  
\_\_\_\_\_ Bronchitis \_\_\_\_\_  
\_\_\_\_\_ TB \_\_\_\_\_  
\_\_\_\_\_ Cancer \_\_\_\_\_  
\_\_\_\_\_ Leukemia \_\_\_\_\_  
\_\_\_\_\_ Hepatitis \_\_\_\_\_  
\_\_\_\_\_ Skin disease \_\_\_\_\_

Any recent illness?

Any known allergies?

Please list present medications and dosage:

Please "check" when completed:

Study explained to patient \_\_\_\_\_ By whom \_\_\_\_\_

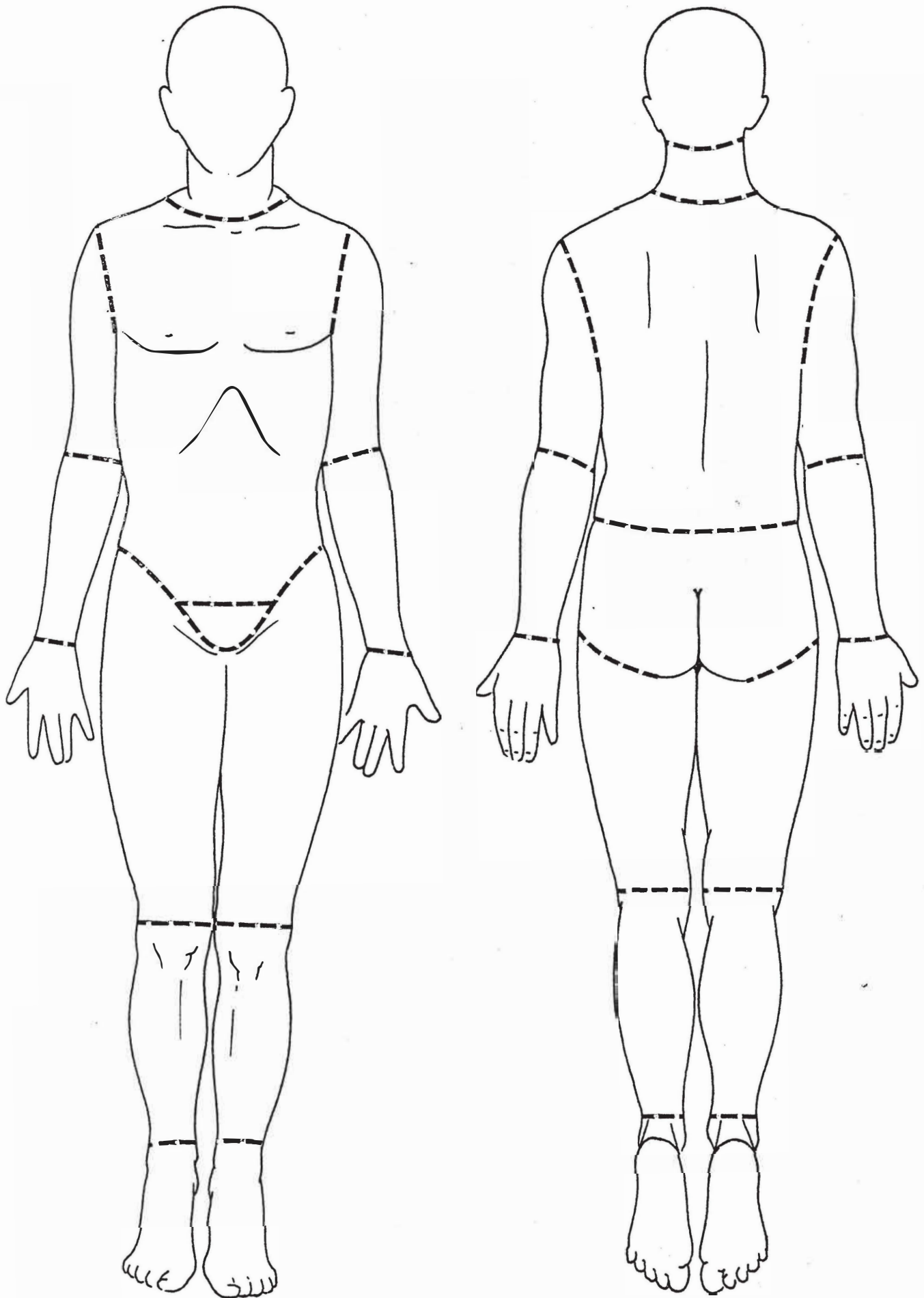
Written permission obtained \_\_\_\_\_

Written home orders given to patient \_\_\_\_\_

Anatomical chart completed showing study areas \_\_\_\_\_  
(Please number grafts for later reference)

Wound cultured \_\_\_\_\_

Wound photographed \_\_\_\_\_



PIGSKIN STUDY

Patient's name \_\_\_\_\_ Date Burned \_\_\_\_\_

Today's date \_\_\_\_\_ Days postburn \_\_\_\_\_

PROCEDURES DONE (please check)

Photos taken (on admission, 4th or 5th day) \_\_\_\_\_ Photo # \_\_\_\_\_

|             | wound<br>cultured | reapplied<br>pigskin<br>(please number) | biopsied | dried<br>pigskin<br>trimmed |
|-------------|-------------------|---|----------|-----------------------------|
| Fresh       | #                 | #                                       | #        |                             |
| Lyophilized | #                 | #                                       | #        |                             |

Other (please specify):

OBSERVATIONS (please circle one in each area)

Adherence of pigskin (amt. exudate) -- please culture if 4 or 5 is circled

|             |                   |                              |                                   |   |   |
|-------------|-------------------|------------------------------|-----------------------------------|---|---|
| Fresh       | 1                 | 2                            | 3                                 | 4                                       | 5   |
| Lyophilized | 1                 | 2                            | 3                                 | 4                                       | 5   |
|             | firmly<br>adhered | in place, but<br>not "tight" | sloughed<br>off during<br>tanking | partially<br>sloughed<br>before tanking | totally sloughed<br>off with removal<br>of dressing |

Gross Inflammation --

|             |                           |   |   |  |  |
|-------------|---------------------------|---|---|--|--|
| Fresh       | 1                         | 2   | 3   | 4  | 5  |
| Lyophilized | 1                         | 2   | 3   | 4  | 5  |
|             | no redness<br>around burn | pink edges<br>extending less<br>than .5cm.<br>around burn | pink to red<br>area around<br>burn from<br>.5cm to 2cm. | red, painful<br>area around<br>burn, extending<br>2+ cm. | red, painful<br>area 2+ cm<br>around burn,<br>with color changes<br>within wound |

Are all areas under fresh pigskin healed? YES / NO

Are all areas under lyophilized pigskin healed? YES / NO

Patient to return to PT (date) \_\_\_\_\_

Signed \_\_\_\_\_

Patient's name \_\_\_\_\_

Cultures --

|             |           |              |               |              |                  |
|-------------|-----------|--------------|---------------|--------------|------------------|
| Fresh       | 1         | 2            | 3             | 4            | 5                |
| Lyophilized | 1         | 2            | 3             | 4            | 5                |
|             | no growth | light growth | medium growth | heavy growth | confluent growth |

Biopsy Report

APPENDIX G

PIGSKIN STUDY

HOME INSTRUCTIONS

1. A light gauze dressing has been applied in physical therapy to hold the pigskin securely. Please leave this entire dressing in place until you return to the hospital so that your wound will stay covered.
2. Please try to keep your burn area clean and dry.
3. You have been given an appointment to come back to physical therapy. Please return when scheduled so that your burn may be cleaned and watched for infection.

Thank you for your cooperation in this study.

## APPENDIX H

### BACTERIAL GROWTH

1. Growth in the inoculated area - very light and light growth  
( $10^1$  to  $10^3$  bacteria per plate)
2. Growth in the primary streak - light to moderate and moderate growth ( $10^3$  to  $10^5$  bacteria per plate)
3. Growth in the secondary streak:
  - a. Moderate to heavy - isolated colonies in the secondary streak ( $10^5$  to  $10^7$  bacteria per plate)
  - b. Heavy - confluent growth in the secondary streak  
( $> 10^7$  bacteria per plate)

Source: Georgiade, N.G.; Lucas, M.; Georgiade R; and Garret, W. "The Use of a New Potent Topical Antimicrobial Agent for the Control of Infection in the Burn Wound," Plastic and Reconstructive Surgery April (1967):349.

---

1.  $10^{-2}$  (1:100) = light growth
2.  $10^{-4}$  (1:10,000) = moderate growth
3.  $10^{-6}$  (1:1,000,000) = heavy growth

Source: Bailey, W.R. and Scott, E.G. "Cultivation of Pathogenic Microorganisms from Clinical Material," Diagnostic Microbiology, 2nd edition. Saint Louis:C.V. Mosby Company, 1966.

APPENDIX I

BIOPSY EVALUATIONS

Patient B

MICROSCOPIC DESCRIPTION:

There is hyperkeratosis, acanthosis, and a mild non-specific inflammatory change in the upper dermis. The changes in specimen B are very similar. Both show a mild inflammation and epithelial hyperplasia to a similar extent compatible with the healing response.

Patient D

MICROSCOPIC DESCRIPTION:

There is hyperkeratosis, acanthosis, and mild chronic inflammatory reaction in the dermis. The changes are approximately the same in both specimens and would be compatible with a healing response.

Patient J

MICROSCOPIC DESCRIPTION:

Two specimens, A & B, show essentially similar changes with mild acanthosis and irregularity of rete ridges with some slight fibrous proliferation and perivascular lymphocytes and histiocytes in the upper dermis. I do not see a significant difference in the tissue response in either specimen.